

Baastrup's disease: a poorly recognised cause of back pain

Farinha F¹, Raínho C², Cunha I¹, Barcelos A¹

ACTA REUMATOL PORT. 2015;40:302-303

A 56-year-old male, with a personal history of obesity (BMI – 50Kg/m²), depression, arterial hypertension, obstructive sleep apnea syndrome and gout, complained about progressive mechanical back pain for more than 10 years. The condition worsened with prolonged orthostatism and spine extension and improved in fetal position. His lumbar spine radiography (Figure 1) revealed enlargement and sclerosis of the spinous processes which was confirmed by computed tomography (CT) (Figures 2 and 3), suggesting Baastrup's disease.

This condition, although previously recognized by others authors, was described in detail by Baastrup, in 1933. It is characterized by enlargement, close approximation and impingement of one spinous process on another (“kissing spines”)¹.

There are few studies on Baastrup's disease epidemiology and their results are inconsistent. A retrospective study analyzed the frequency of Baastrup's disease evidence in abdominopelvic CT scans of 1008 patients, reporting a prevalence of 41%. After the age of 80, prevalence was 81.3%². Another study determined the prevalence of interspinous bursitis in 539 symptomatic patients who underwent magnetic resonance (MRI) and obtained a result of 8.2%¹. A smaller study using a diagnostic algorithm to evaluate 156 patients with recurrent back pain, found 3 cases (1.8%) in which Baastrup's disease was responsible for the symptoms³.

Patients often complain of back pain, typically increased with extension and relieved by flexion.

Radiographically, spinous process impingement leads to reactive sclerosis, enlargement, flattening, and remodeling of the involved vertebral spines². Physicians frequently miss it on radiographs due to lack of knowledge and overexposure of spinous processes in most X rays⁴. This abnormal contact between adjacent spinous

processes can result in neoarthrosis and formation of an adventitious bursa, which can be seen pathologically and on MRI^{1,2}.

Differential diagnosis should be made with other causes of low back pain, more frequently lumbar internal disc disruption, facet joint pain and sacroiliac joint pain³.

Both conservative and surgical options are available for treatment. It may improve with localized interspinous injection of anesthetic and there are conflicting reports of improvement with partial excision of the spinous process⁴.

In conclusion, Baastrup's disease should be considered in differential diagnosis of back pain, although one

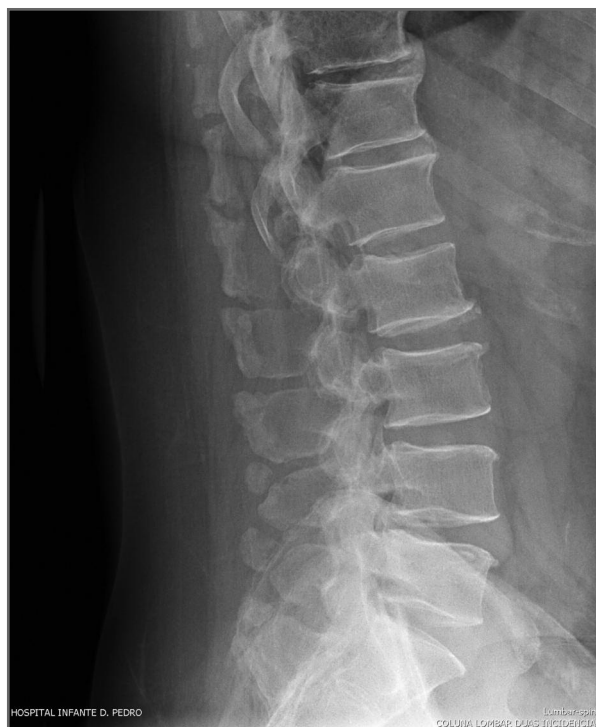

FIGURE 1. Lumbar spine radiography (lateral view)

1. Serviço de Reumatologia, Centro Hospitalar do Baixo Vouga EPE, Aveiro

2. USF Flor de Sal

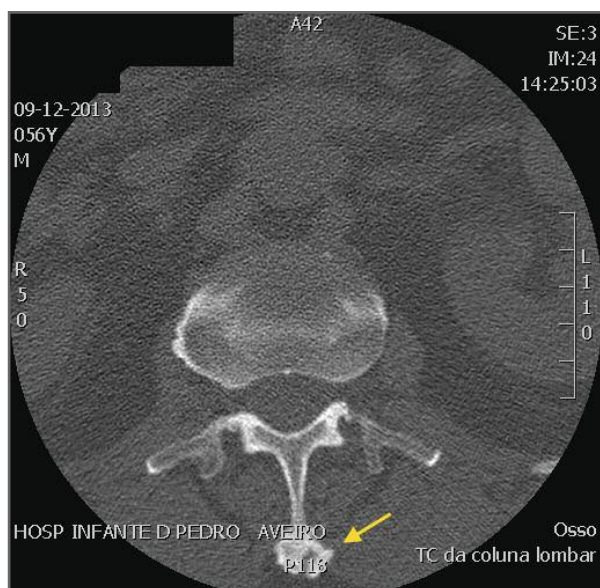


FIGURE 2. Lumbar CT (axial view) showing enlargement of the spinous process

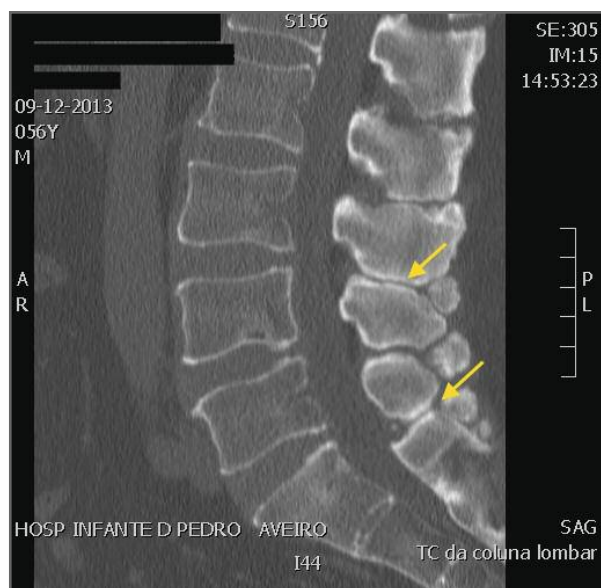


FIGURE 3. Lumbar CT (sagittal view) revealing approximation of the spinous processes with reactive sclerosis

must be aware the typical radiographic changes appear to be common with aging and may not be the cause of patient's symptoms.

CORRESPONDENCE TO

Filipa Farinha
 Serviço de Reumatologia - Centro Hospitalar do Baixo Vouga
 Avenida Artur Ravara
 3814-501 Aveiro
 E-mail: filipa.mcfarina@gmail.com

REFERENCES

1. Maes R, Morrison WB, Parker L, Schweitzer ME, Carrino JA. Lumbar Interspinous Bursitis (Baastrup Disease) in a Symptomatic Population: Prevalence on Magnetic Resonance Imaging. *Spine*. 2008; 33(7):E211–E215.
2. Kwong Y, Rao N, Latief K. MDCT Findings in Baastrup Disease: Disease or Normal Feature of the Aging Spine? *Am J Roentgenol*. 2011; 196(5):1156–1159.
3. DePalma MJ, Ketchum JM, Saullo T. What Is the Source of Chronic Low Back Pain and Does Age Play a Role?: Chronic Low Back Pain and Age. *Pain Med*. 2011; 12(2):224–233.
4. Singla A, Shankar V, Mittal S, Agarwal A, Garg B. Baastrup's disease: The kissing spine. *World J Clin Cases*. 2014;2(2):45-47.