

LETTERS TO THE EDITOR

# Pseudotumoral calcinosis of the spine in systemic sclerosis - an atypical location

Rato M<sup>1</sup>, Rocha TM<sup>1</sup>, Bernardo A<sup>1</sup>, Costa L<sup>1</sup>

To the editor,

Systemic sclerosis (SSc) is an immune-mediated rheumatic disease that is characterized by fibrosis of the skin and internal organs and vasculopathy<sup>1</sup>. Calcinosis is a well-recognized and potentially debilitating manifestation of disease that consists of deposition of insoluble calcium in soft tissue<sup>2,3</sup>. Prevalence of calcinosis has been reported to be 18-49%<sup>2</sup>. Although its pathogenesis is unclear, there is evidence supporting mechanical stress, insufficient blood flow, tissue hypoxia and chronic inflammation as potential mechanisms involved<sup>4</sup>. In most patients, calcified areas are quite small and localized under the skin<sup>5</sup>. Little is known about the occurrence of large calcified masses in SSc, which are rarely reported (< 1% of patients)<sup>6</sup>. However, a recent literature review mentions its occurrence in about 3% of patients with SSc<sup>7</sup>. Furthermore, calcinosis around the spine, especially large calcified masses, is a

quite rare event, with only a few cases described in the literature<sup>7</sup>.

A 60-year-old Caucasian woman was diagnosed with a limited cutaneous SSc at the age of 54 and was under treatment with nifedipine (60mg/daily). The diagnosis was made by the presence of sclerodactyly, Raynaud's phenomenon, microstomy, active scleroderma pattern in nailfold videocapillaroscopy and anti-nuclear antibodies (title 1/1000), with positivity for anticentromere antibodies. No signs of cutaneous calcinosis were identified. No pulmonary or renal involvements were present at baseline. She had a medical history of osteoporosis under therapy with zoledronic acid for 4 years. In a routine evaluation, she reported a 4-month history of mechanical back pain and the appearance of a mass in the left paravertebral region. She denied previous trauma. Physical examination revealed the presence of a left paravertebral mass, located at dorsolumbar junction, with hard consistency, immobile, painful on palpation, measuring approximately 7 cm in the longest axis. There were no limitations in active range of motion. No neurological signs indicating impairment of spinal cord or nerve roots were observed. The anteroposterior radiograph of the spine showed a left paravertebral radi-

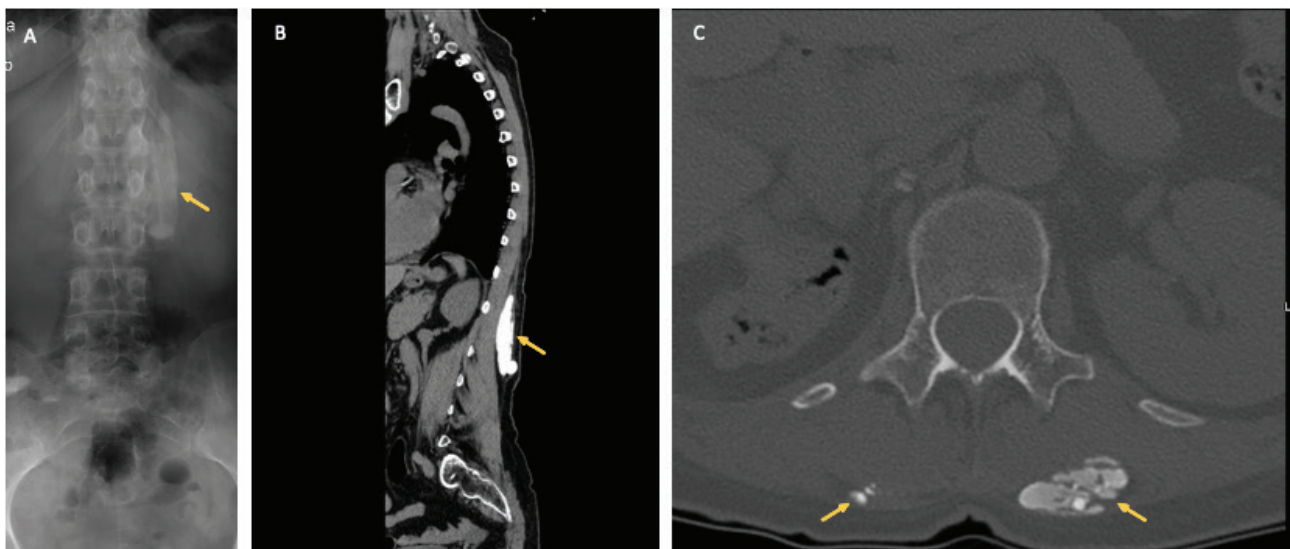
<sup>1</sup> Serviço de Reumatologia, Centro Hospitalar Universitário de São João

Submitted: 03/01/2022

Accepted: 04/03/2022

Correspondence to: Maria Seabra Rato

E-mail: maria.rato9@gmail.com



**Figure 1.** Paravertebral calcinosis. A. Anteroposterior radiograph of the spine showing a left paravertebral radiopaque lesion. B. Computed tomography (CT) of the spine (sagittal plane) revealing a calcified mass in the paravertebral muscles extending from the 12th dorsal to the 3rd lumbar vertebra. C. Cross-sectional CT image of 1st lumbar vertebra exhibiting a polylobed mass in the left paravertebral muscles and microcalcification on the right side.

opaque lesion (Figure 1A) and the thoracolumbar spine computed tomography (CT) revealed the presence of calcified and polylobed mass in the left paravertebral muscle, extending from the 12th dorsal to the 3rd lumbar vertebra, with approximately 8cm in the longest axis, without osteolysis or any compression of the adjacent neurological structures (Figure 1B). Microcalcifications in the right paravertebral muscles was also seen (Figure 1C). Plasmatic and urinary phosphorus and calcium levels, renal function tests, plasma parathyroid hormone level and vitamin D were all within the normal range. A diagnosis of pseudotumoral calcinosis secondary to SSc was made. After reviewing the medical record, bilateral paravertebral muscle microcalcifications were found to be already present in a thoracic CT performed 5 years before, although these findings have not been reported. Nifedipine was changed to diltiazem (180mg/daily). Symptomatic treatment with analgesics allowed a significant improvement of clinical symptoms. The patient remains regularly followed up in the Rheumatology outpatient clinic.

Calcinosis around the spine can cause local pain, bone destruction and neurological involvement due to spinal cord or nerve roots compression<sup>8</sup>. Among spinal forms, cervical region is the most frequently involved<sup>7,8</sup> making a calcinosis in dorsolumbar region is an even rarer finding<sup>7</sup>. There is no effective medical therapy for calcinosis, which is often limited to analgesic therapy or, in more severe cases, to surgical resection of calcium deposits<sup>2,9</sup>. Our patient was medicated with bisphosphonate for osteoporosis that did not prevent the progression of calcinosis lesions. The authors switched from nifedipine to diltiazem because there are more

studies compared to other calcium channel blockers, although its effectiveness has not been clearly determined<sup>9</sup>.

The documentation of this clinical case alerts to the possibility of unusual locations of calcinosis in SSc and the need to identify targeted pharmacological therapies capable of preventing or reducing calcinosis lesions.

## REFERENCES

1. Denton CP, Khanna D. Systemic sclerosis. *Lancet*. 2017;390(10103):1685-1699. doi:10.1016/S0140-6736(17)30933-9.
2. Valenzuela A, Song P, Chung L. Calcinosis in scleroderma. *Curr Opin Rheumatol*. 2018;30(6):554-561. doi:10.1097/BOR.0000000000000539.
3. Chander S, Gordon P. Soft tissue and subcutaneous calcification in connective tissue diseases. *Curr Opin Rheumatol*. 2012;24(2):158-164. doi:10.1097/BOR.0b013e32834ff5cd.
4. Avouac J, Guerini H, Wipff J, Assous N, Chevrot A, Kahan A, et al. Radiological hand involvement in systemic sclerosis. *Ann Rheum Dis* 2006;65:1088-92.
5. Hachulla E, Launay D. Diagnosis and classification of systemic sclerosis. *Clin Rev Allergy Immunol*. 2011;40(2):78-83. doi:10.1007/s12016-010-8198-y.
6. Ngo S, Vandhuick T, Janvresse A, Levesque H, Marie I. Des calcifications pseudotumorales [Pseudotumoral calcinosis]. *Rev Med Interne*. 2011;32(4):251-252. doi:10.1016/j.revmed.2010.05.004.
7. Zanatta E, Desportes M, Do HH, et al. Pseudotumoral calcinosis in systemic sclerosis: Data from systematic literature review and case series from two referral centres. *Semin Arthritis Rheum*. 2020;50(6):1339-1347. doi:10.1016/j.semarthrit.2020.03.009.
8. Sambataro D, Sambataro G, Zaccara E, Maglione W, Vitali C, Del Papa N. Tumoral calcinosis of the spine in the course of systemic sclerosis: report of a new case and review of the literature. *Clin Exp Rheumatol*. 2015;33(4 Suppl 91):S175-S178.
9. Richardson C, Plaas A, Varga J. Calcinosis in Systemic Sclerosis: Updates in Pathophysiology, Evaluation, and Treatment. *Curr Rheumatol Rep*. 2020;22(10):73. doi:10.1007/s11926-020-00951-2.