

Juvenile dermatomyositis: a severe and atypical presentation

Moitinho de Almeida I^{1*}, Abreu Andrade M¹, Bernardo M^{1,2}, Fonseca AC³, Campanilho Marques R^{1,2}, Oliveira Ramos F^{1,2}, Costa-Reis P^{1,2}

¹ Unidade de Reumatologia Pediátrica, Hospital de Santa Maria, Lisbon, Portugal

² Faculdade de Medicina, Universidade de Lisboa, Lisbon, Portugal

³ Serviço de Oftalmologia, Hospital de Santa Maria, Lisbon, Portugal

* ORCID: 0000-0003-2439-1141

Correspondence to

Isabel Moitinho de Almeida

E-mail:

Submitted: 10/02/2025

Accepted: 22/03/2025

This article has been accepted for publication and undergone full peer review but has not been through the copyediting, typesetting, pagination and proofreading process which may lead to differences between this version and the Version of Record. Please cite this article as an 'Accepted Article'

© 2025 Portuguese Society of Rheumatology

This article is protected by copyright. All rights reserved.

ABSTRACT

Introduction: Juvenile dermatomyositis (JDM) is a rare immune-mediated disease, characterised by proximal muscle weakness and typical skin rashes¹. We present a patient with severe JDM, to highlight the importance of a timely diagnosis and early initiation of treatment.

Case description: A 9-year-old girl presented to the hospital due to asthenia, rash, generalized oedema, and inability to walk. At observation, the patient had dysphonia, dysphagia, proximal muscle weakness, petechial rash, skin ulcers, and anasarca. The levels of creatine kinase, aldolase, transaminases, and ferritin were elevated, and the NXP-2 antibody was detected. Prednisolone and methotrexate were started, followed by intravenous immunoglobulin. During the hospitalisation, the patient had an alveolar haemorrhage. Retinal vasculitis was also detected. Mycophenolate mofetil was added to the treatment. The patient had full resolution of myositis with progressive recovery of muscle strength, healed ulcers, and completely improved vision.

Discussion: This is an atypical presentation of JDM, without the typical skin lesions, but with several manifestations of severe vasculopathy, including retinopathy and alveolar haemorrhage. Early diagnosis and a multidisciplinary approach are crucial to improve prognosis.

Keywords: Inflammation; Muscle; Pediatric/Juvenile Rheumatology; Autoantigens and Autoantibodies; Dermatomyositis.

Introduction

Juvenile dermatomyositis (JDM), while being the most common form of idiopathic inflammatory myopathy in children, is a rare condition with an annual incidence of approximately 2-4 patients per one million children¹⁻⁴ and an estimated prevalence of 4 in 100 000⁵. It is characterised by proximal and symmetrical muscle weakness, as well as characteristic skin rashes such as heliotrope rash and Gottron's papules¹. Although the precise aetiology of JDM remains unclear, it is believed to result from environmental triggers acting on genetically predisposed children⁶. Females are more frequently affected than males, with a peak incidence typically between 5 to 10 years of age³.

Diagnosis of JDM relies on a combination of clinical and laboratory findings. The 1975 classification criteria proposed by Bohan and Peter⁷ included electromyography and muscle biopsy as key components. These criteria were revised in 2017 by the European League Against Rheumatism (EULAR) and the American College of Rheumatology (ACR)⁸. The revised criteria excluded electromyography and incorporated a scoring system that adjusts for whether a muscle biopsy was performed, as these two procedures are often not performed in clinical practice due to their invasive nature. Additionally, using muscle MRI to detect muscle oedema has become a valuable non-invasive tool, particularly in cases of diagnostic uncertainty⁶. A thorough clinical examination is warranted, incorporating validated tools for assessing muscle strength, such as Childhood Myositis Assessment Scale (CMAS) or manual muscle testing of standardized eight muscle groups (MMT8)⁹. The clinical presentation of JDM can be highly variable, ranging from mild symptoms to severe, life-threatening complications, including vasculopathy and multi-organ involvement¹⁰. This variability, combined with its rarity, often delays diagnosis.

In recent years, the prognosis for children with JDM has significantly improved, largely due to advances in treatment options. Prior to the widespread use of corticosteroids, mortality rates were high and many patients experienced severe disability⁹. Current first-line treatment options typically still include corticosteroids and other immunosuppressive agents tailored to disease severity, which has contributed to a significant decline in mortality, now reported to be below 4%¹¹. Early recognition and diagnosis are crucial, as timely initiation of immunosuppressive therapy can significantly improve prognosis and reduce morbidity¹¹.

Here, we describe a severe case of JDM with an atypical presentation, aiming to underline the importance of heightened clinical suspicion and the prompt initiation of appropriate treatment to optimise patient outcomes.

Case report

A 9-year-old female patient, with no relevant previous medical history, presented with a macular rash on her neck and chest. The child was evaluated at a hospital, where elevation of transaminases was detected - aspartate aminotransferase (AST) 295 U/L, alanine aminotransferase (ALT) 94 U/L. A viral infection was suspected. A week later, there was significant facial swelling and worsening of the rash, with mucopurulent discharge from the skin lesions, prompting her paediatrician to start treatment with 1 mg/Kg/day of oral prednisolone, along with oral amoxicillin and clavulanic acid for impetigo.

Her condition progressively worsened over the following weeks, despite being on corticosteroid therapy, and by the time the child presented at a tertiary hospital, approximately one month after the first symptoms, the patient had developed generalised oedema, proximal muscle weakness and a widespread rash. No fever, oral ulcers, dyspnoea, cough, arthralgias, myalgias, changes in urine appearance, visual disturbances, or Raynaud's phenomenon were reported.

On physical examination, the patient was ill-appearing, with normal capillary refill time and normal vital signs. Dysphonia, dysphagia and symmetrical proximal muscle weakness (MMT8-24/80) were detected. There was anasarca, with significant oedema of the face, abdomen, and limbs (Figure 1). Lesions compatible with impetigo were identified on the patient's face (Figure 1). There was also a petechial rash on the neck and ears (Figure 2) and cervical, axillary, and perineal ulcers (Figure 3). Livedo reticularis was also detected. There was no heliotrope rash or Gottron's papules. There was no arthritis. Adenomegalies or hepatosplenomegaly were not identified, and respiratory involvement was absent. An ophthalmological assessment showed no alterations.

Initial laboratory assessment revealed normal haemoglobin levels (14.5 g/dL), mild leukocytosis (13 300/ μ L) with neutrophilia (10 770/ μ L), a normal lymphocyte count (1060/ μ L), mild thrombocytopenia (140 000/ μ L), hypoalbuminaemia (3.1 g/dL), and elevated ferritin (1 949 ng/mL), transaminases (AST 792 337 U/L, ALT 337 U/L), lactate dehydrogenase (LDH) (1 109 U/L) and creatine kinase (CK) (9 317 U/L) serum levels. C-reactive protein was 0.46 mg/dL, and the erythrocyte sedimentation rate was 12 mm/hour. Aldolase serum levels were elevated (79 U/L). Complement evaluation, including C3c, C4 and CH50, was within normal limits. Later, nuclear

matrix protein 2 (NPX-2) autoantibody was detected. Antinuclear antibodies and anti-cytoplasmic antibodies were negative. An echocardiogram and an abdominal ultrasound were performed and were normal.

Juvenile dermatomyositis was suspected, and the patient was admitted to the hospital. Prednisolone was increased to 2 mg/kg/day intravenously, and subcutaneous methotrexate (15 mg/m²/week) was started. Due to the severity of skin involvement, intravenous immunoglobulin (IVIG) at 2 g/Kg/month was also initiated. Antibiotic therapy was adjusted to clindamycin, and later linezolid for a total of 14 days. Due to dysphagia, she was initially fed via a nasogastric tube. Physiotherapy, speech therapy, and psychological support were initiated. During hospitalisation, Gottron's papules became apparent. The patient developed a urinary tract infection caused by *Pseudomonas aeruginosa* and sepsis caused by *Serratia marcescens*, treated with meropenem for 14 days.

The day after the sepsis diagnosis was made, the patient experienced a sudden episode of dyspnoea, hypoxaemia, and haemoptysis, suggestive of alveolar haemorrhage. Pulmonary auscultation revealed decreased breath sounds on the left hemithorax and localized crackles. A chest radiograph was compatible with this diagnosis (Figure 4). A bronchoscopy revealed bloody secretions in the bronchi and the pulmonary CT scan revealed findings consistent with diffuse alveolar haemorrhage and areas of ground-glass consolidation (Figure 5). Supplemental oxygen (maximum Fraction of Inspired Oxygen of 40% via Venturi mask) was administered. Due to acute anaemia (minimum haemoglobin of 5.7 g/dL), the patient was transfused with red blood cell concentrate. The patient showed progressive respiratory improvement, with decreasing supplemental oxygen requirement, which was discontinued six days later.

Despite these major complications, there was a progressive improvement in muscle strength and resolution of myositis, with normalization of CK, LDH, AST, ALT and aldolase serum levels. Additionally, the patient demonstrated marked improvement in the skin lesions, particularly after starting IVIG therapy. At discharge, after 32 days of hospitalization, there was nearly complete epithelialisation of the ulcers and significant improvement in muscle strength.

During follow-up, respiratory evaluation included spirometry, plethysmography, and diffusion capacity of the lungs for carbon monoxide, which revealed no abnormalities. A follow-up pulmonary CT scan demonstrated complete resolution of previous findings.

Furthermore, due to complaints of diminished vision, the patient was evaluated by an ophthalmologist, who identified bilateral choroidoretinal micro-occlusive changes in the posterior poles, compatible with a vasculitic process (Figure 6). Mycophenolate mofetil was

introduced, 600 mg/m²/dose every 12 hours, alongside prophylactic cotrimoxazole to prevent a *Pneumocystis jirovecii* infection. Corticosteroids were gradually tapered until complete discontinuation.

Currently, a year after diagnosis, the patient has normal muscle strength (MMT8-80), and no skin lesions occurred. No calcinosis was detected. There has been a progressive improvement in visual acuity, which is now normal. A reduction of the bilateral retinal lesions has been seen. The patient maintains a multidisciplinary follow-up with paediatric rheumatology, paediatric pulmonology, ophthalmology and physical medicine and rehabilitation.

Discussion

JDM is a rare, multisystemic disease with highly variable clinical manifestations that extend beyond its hallmark symptoms of muscle weakness and classic rashes. The systemic involvement observed in severe cases, such as the one described here, highlights the unpredictable and potentially life-threatening nature of JDM.

The patient we report illustrates an unusual initial presentation of JDM, marked by significant oedema, petechial rash, ulcers, and the initial absence of typical skin rashes. Skin ulceration, observed in this case, is a predictor of worse prognosis and may indicate vasculopathy in other organs, such as retinopathy and alveolar haemorrhage¹², both of which were present in this patient. While interstitial lung disease is the most common pulmonary manifestation in children with JDM, diffuse alveolar haemorrhage, although rare, is a potentially fatal complication. Diffuse alveolar haemorrhage often presents with acute respiratory distress, haemoptysis, hypoxaemia, anaemia, and diffuse infiltrates on chest imaging, as was the case in our patient. Diagnosis can be confirmed by bronchoscopy, revealing a haemorrhagic bronchoalveolar lavage. It typically arises during the active phase of the disease due to inflammation and damage to the alveolar capillaries^{13,14}.

Retinopathy is an even rarer complication of JDM, first documented in 1938¹⁵. Since then, only a limited number of case studies have reported its occurrence in both children and adults. Vasculitis with damage to capillary endothelial cells may contribute to its pathogenesis¹⁶. This can lead to reduced visual acuity, which is potentially reversible with adequate disease control, and only rarely evolves to persistent and profound vision loss, caused by macular haemorrhage or oedema and optic atrophy^{17,18}.

The detection of NXP-2 autoantibody provides further insight into the severity and unique features of this case. In children, NXP-2 autoantibody is usually associated with calcinosis, dysphagia, oedema and more severe muscle weakness. Distinct clinical manifestations observed in patients with different autoantibody profiles suggest that personalized, targeted therapeutic approaches may be the future in JDM management^{19,20}. Our patient has not exhibited calcinosis, a well-recognized and debilitating complication of JDM that is frequent in patients with NXP-2 positive autoantibodies¹⁹, highlighting the need for continuous clinical vigilance.

In the absence of international consensus on the diagnosis and treatment of JDM, the Single Hub and Access point for paediatric Rheumatology in Europe (SHARE) initiative was established to standardize care across Europe. This initiative led to the development of recommendations through an evidence-informed consensus process, for diagnosis and management of JDM. In accordance with these recommendations, immunomodulating agents are often used to reduce cumulative corticosteroids dose, as was the case with our patient. Methotrexate is the most commonly used immunomodulating agent at diagnosis, alongside corticosteroids, due to its favourable safety profile. Alternative options include cyclosporine A, azathioprine and mycophenolate mofetil. In cases with prominent skin involvement, intravenous immunoglobulin should be considered. For severe and/or refractory disease, adding another immunomodulating agent from the options above or considering rituximab, anti-TNF therapies, or JAK inhibitors may be warranted^{11,21–23}. Our patient's progressive recovery, with the resolution of muscle weakness, skin ulcers and respiratory symptoms, following immunosuppressive therapy and multidisciplinary care, highlights the positive impact of early and aggressive treatment. Furthermore, the use of IVIG in our patient helped accelerate the healing of skin ulcers. Although the initial presentation was severe, marked by life-threatening complications, such as diffuse alveolar haemorrhage, the recovery has been promising, as the patient currently shows no major sequelae.

This patient highlights the value of a multidisciplinary approach in the management of JDM, integrating psychological and physiotherapy alongside medical treatment to address the multifaceted impact of the disease, which is known to significantly affect quality of life. Cooperative multidisciplinary care is essential to improve not only clinical outcomes but also the overall well-being of patients.

In conclusion, this case highlights the diverse clinical spectrum of JDM, the importance of early and aggressive therapy, and the benefits of a multidisciplinary approach. It serves as a reminder

of the importance of maintaining a high index of suspicion for JDM, even in patients with atypical presentations, to ensure timely diagnosis and effective management to optimize outcomes and quality of life.

Accepted manuscript

Figures

Figure 1. Patient at presentation with marked facial oedema and facial impetigo.

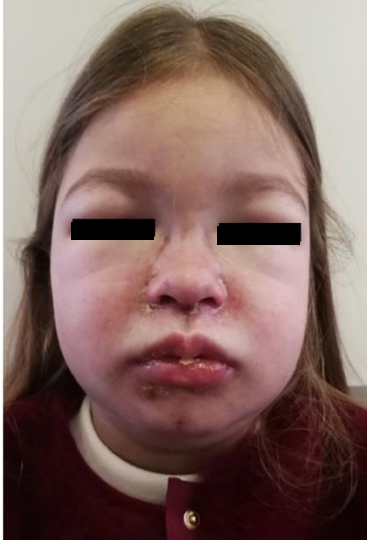

Figure 2. Visible cervical ulcers identified at presentation.

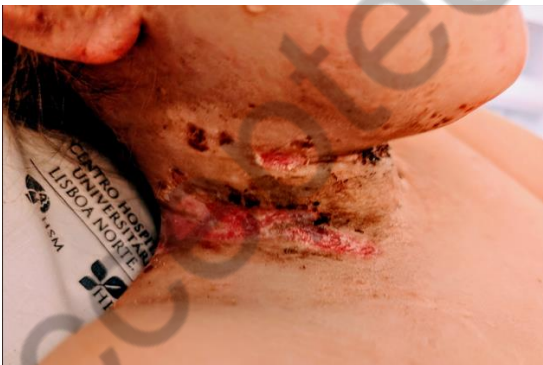

Figure 3. Cervical ulceration as well as an auricular and cervical petechial rash identified at presentation.

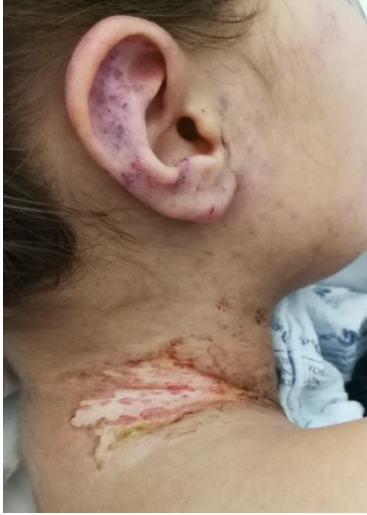

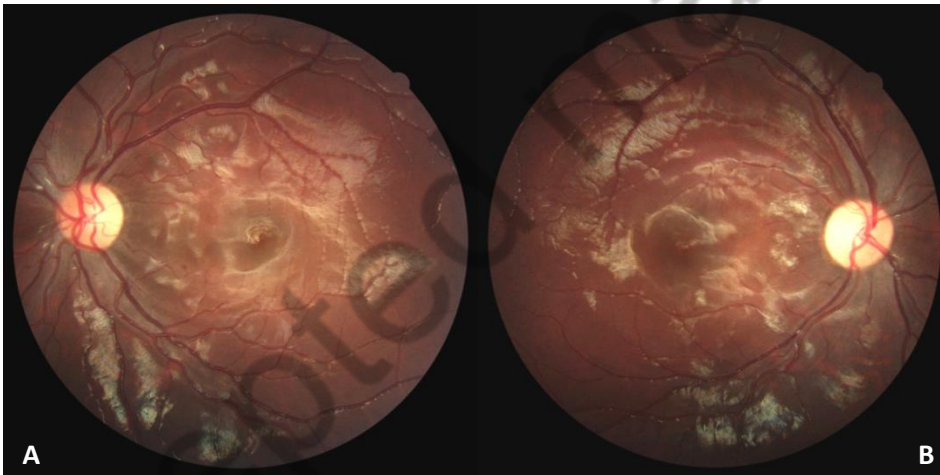
Figure 4. Chest radiograph showing a left white lung.

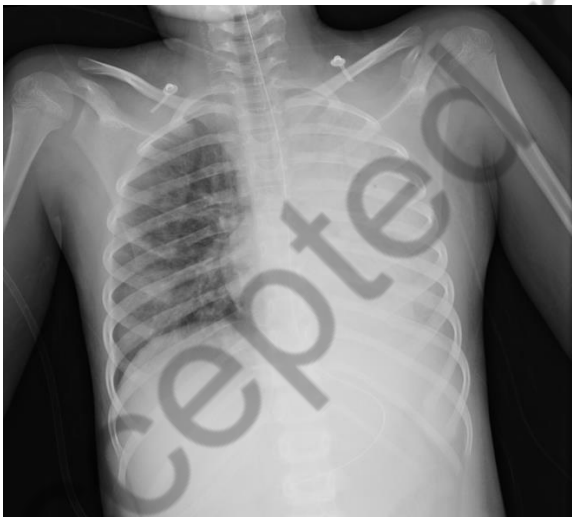

Figure 5. Pulmonary CT scan showing a left white-lung, consistent with diffuse alveolar haemorrhage and areas of ground-glass consolidation.

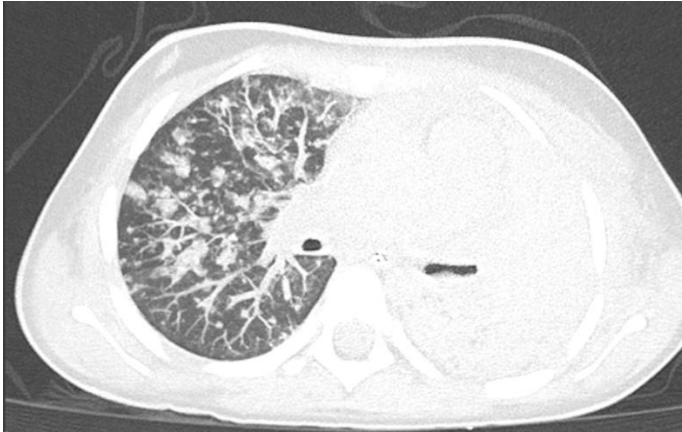

Figure 6 (A and B). Retinoscopy showing bilateral choroidoretinal micro-occlusive changes detected in the posterior pole, compatible with a vasculitic process.



References

1. Meyer A, Meyer N, Schaeffer M, Gottenberg JE, Geny B, Sibilia J. Incidence and prevalence of inflammatory myopathies: a systematic review. *Rheumatology*. 2014; 54: 50-63.
<https://doi.org/10.1093/rheumatology/keu289>
2. Pelkonen P, Jalanko H, Lantto R, et al. Incidence of systemic connective tissue diseases in children: a nationwide prospective study in Finland. *J Rheumatol*. 1994; 21: 2143-2146.
3. Symmons D, Sillis J, Davis S. The incidence of juvenile dermatomyositis: results from a nation-wide study. *Br J Rheumatol*. 1995; 34: 732-736.
<https://doi.org/10.1093/rheumatology/34.8.732>
4. Mendez E, Lipton R, Ramsey-Goldman R, et al. US incidence of juvenile dermatomyositis, 1995-1998: results from the National Institute of Arthritis and Musculoskeletal and Skin Diseases Registry. *Arthritis Rheum*. 2003; 49: 300-305. <https://doi.org/10.1002/art.11122>
5. Moegle C, Severac F, Lipsker D. Epidemiology of juvenile dermatomyositis in Alsace. *Br J Dermatol*. 2019; 182: 1307-1308. <https://doi.org/10.1111/bjd.18799>
6. M. Feldman B, G Rider L, M Reed A, M Pachman L. Juvenile dermatomyositis and other idiopathic inflammatory myopathies of childhood. *Lancet*. 2008; 371: 2201-2212.
[https://doi.org/10.1016/S0140-6736\(08\)60955-1](https://doi.org/10.1016/S0140-6736(08)60955-1)
7. Bohan A, Peter J. Polymyositis and dermatomyositis (first of two parts). *New Engl J Med*. 1975; 292: 344-347. <https://doi.org/10.1056/NEJM197502132920706>
8. Lundberg I, Tjärnlund A, Bottai M, et al. 2017 European League Against Rheumatism/ American College of Rheumatology classification criteria for adult and juvenile idiopathic inflammatory myopathies and their major subgroups. *Ann Rheum Dis*. 2017; 69: 2271-2282.
<https://doi.org/10.1136/annrheumdis-2017-212786>
9. Martin N, K.Li C, R. Wedderburn L. Juvenile dermatomyositis: new insights and new treatment strategies. *Ther Adv Musculoskelet Dis*. 2012; 4: 41-50.
<https://doi.org/10.1177/1759720X11424460>
10. Soumaya G, Radia T, Mikel E, Noureddine L. Juvenile dermatomyositis. *StatPearls*. Published Online First: 16 January 2023. <https://pubmed.ncbi.nlm.nih.gov/30480969/>
11. Bellutti Enders F, Bader-Meunier B, Baildam E, et al. Consensus-based recommendations for the management of juvenile dermatomyositis. *Ann Rheum Dis*. 2016; 76: 329-340.
<https://doi.org/10.1136/annrheumdis-2016-209247>
12. Papadopoulou C, McCann LJ. The Vasculopathy of Juvenile Dermatomyositis. *Front Pediatr*. 2018; 6: 1-8. <https://doi.org/10.3389/fped.2018.00284>
13. Carneiro da Silva EC, Monteiro Bugni V, de Sande e Lemos Ramos Ascensão Terreri MT, de Oliveira Castro MH, de Souza Ishigai MM, Esteves Hilário MO. Juvenile dermatomyositis (JDM) and severe pulmonary involvement: case report. *Rev Bras Rheumatol*. 2009; 49: 462-467. <https://doi.org/10.1590/S0482-50042009000400012>

14. Kim SJ, Kim KH, Kim TS, Han SS, Moon KW. A Case of a Patient with Dermatomyositis Who Developed a Diffuse Alveolar Hemorrhage. *J Rheum Dis.* 2011; 18: 125-128.
<https://doi.org/10.4078/jrd.2011.18.2.125>
15. Gordon M B. Retinitis in dermatomyositis. *Trans Am Ophthalmol Soc.* 1938; 36: 282-296.
16. Yan Y, Shen X. Purtscher-like retinopathy associated with dermatomyositis. *BMC Ophthalmol.* 2013; 13: 1-3. <https://doi.org/10.1186/1471-2415-13-36>
17. Akikusa JD, K. Tennankore D, V. Levin A, M. Feldman B. Eye findings in patients with juvenile dermatomyositis. *J Rheumatol.* 2005; 32: 1986-1991.
18. Backhouse O, Griffiths B, Henderson T, Emery P. Ophthalmic manifestations of dermatomyositis. *Ann Rheum Dis.* 1998; 57: 447-449. <https://doi.org/10.1136/ard.57.8.447>
19. Calvão J, Isidoro Azeiteiro AR, Gonçalves M. A Importância dos Novos Autoanticorpos Específicos da Dermatomiosite. *Rev Port Derm Venereol* 2019. 2019; 77: 15-24.
<https://doi.org/10.29021/spdv.77.1.1021>
20. Albayda J, Pinal-Fernandez I, Huang W, et al. Dermatomyositis patients with anti-nuclear matrix protein-2 autoantibodies have more edema, more severe muscle disease, and increased malignancy risk. *Arthritis Care Res (Hoboken).* 2017; 69: 1771-1776.
<https://doi.org/10.1002/acr.23188>
21. Ramanan A, Campbell-Webster N, Ota S, et al. The effectiveness of treating juvenile dermatomyositis with methotrexate and aggressively tapered corticosteroids. *Arthritis Rheum.* 2005; 52: 3570-3578. <https://doi.org/10.1002/art.21378>
22. Kim H. Juvenile Dermatomyositis: Updates in Pathogenesis and Biomarkers, Current Treatment, and Emerging Targeted Therapies. *Pediatr Drugs.* 2024; 27: 57-72.
<https://doi.org/10.1007/s40272-024-00658-2>
23. Cassard L, Seraly N, Riegert M, Patel A, Fernandez AP. Dermatomyositis: Practical guidance and unmet needs. *Immunotargets Ther.* 2024; 13: 151-172.
<https://doi.org/10.2147/ITT.S381472>