

## Oesophageal Involvement in Behçet's disease: a case-based literature review

[Pontes Ferreira M](#)<sup>1</sup>, Cunha A<sup>1</sup>, [Almeida S](#)<sup>1</sup>, Azevedo S<sup>1</sup>, [Santos-Faria D](#)<sup>1</sup>, Guimarães F<sup>1</sup>, Tavares-Costa J<sup>1</sup>

<sup>1</sup> Rheumatology Department, Unidade Local de Saúde do Alto Minho, Ponte de Lima, Portugal

### Correspondence to

Maria Pontes Ferreira

E-mail: [mjpontesferreira@gmail.com](mailto:mjpontesferreira@gmail.com)

**Submitted:** 02/11/2025

**Accepted:** 29/12/2025

This article has been accepted for publication and undergone full peer review but has not been through the copyediting, typesetting, pagination and proofreading process which may lead to differences between this version and the Version of Record. Please cite this article as an 'Accepted Article'

© 2026 Portuguese Society of Rheumatology

This article is protected by copyright. All rights reserved.

**Abstract**

Behçet's disease is a rare, chronic, multisystemic disorder with heterogeneous clinical presentations, ranging from mucocutaneous to neurological, arterial and ocular involvement. Gastrointestinal manifestations occur in 1 to 60% of patients, with marked geographic disparity. Oesophageal involvement is exceptionally rare and may result in substantial morbidity. We describe a 67-year-old woman with Behçet's disease with recurrent food impaction, progressive dysphagia, and marked weight loss. Endoscopies revealed oesophageal ulceration and narrowing; barium transit study showed marked proximal oesophageal stenosis. Despite treatment with glucocorticoids, colchicine and azathioprine, dysphagia and stenosis worsened and oesophageal dilatation was considered unsafe due to mucosal friability. Biological treatment with adalimumab was initiated, leading to clinical stabilization and no further progression of the stenosis. This case illustrates a rare and severe manifestation of Behçet's disease and highlights the diagnostic and therapeutic challenges of oesophageal involvement. A review of published cases suggests that oesophageal BD remains under-recognized, with biologic therapy emerging as a promising option in refractory disease. Early suspicion is essential in patients with unexplained dysphagia to prevent irreversible complications.

**Keywords:** Behçet's disease; Biological therapies; Oesophagus; Endoscopy; Adalimumab

## Introduction

Behçet's disease (BD) is a rare, multisystemic, relapsing–remitting inflammatory disorder, characterized by heterogeneous clinical manifestations, including mucocutaneous, articular, ocular, vascular, and neurological involvement<sup>1</sup>. Gastrointestinal (GI) manifestations occur with similar frequency in both male and female patients, though reported prevalence varies geographically from 1 to 60%<sup>1</sup>.

Although rare, oesophageal involvement can lead to severe complications such as stricture formation, dysphagia, and malnutrition <sup>2</sup>, resulting in significant morbidity. To date, only a limited number of cases of oesophageal Behçet's disease have been reported<sup>3</sup>, highlighting the clinical significance of documenting new presentations.

Here we report a case of oesophageal involvement in BD, emphasizing its clinical relevance and the associated diagnostic challenges and therapeutic considerations, and provide a brief review of the current evidence.

## Clinical case

A 67-year-old woman has been followed in our department with the diagnosis of BD since the age of 55, with mucocutaneous involvement (oral and genital ulcers and pseudofolliculitis) and vascular involvement (recurrent thrombophlebitis), treated with low-dose glucocorticoids and colchicine 1 mg/day, with reasonable clinical response.

In 2018, at the age of 60, she presented sudden episodes of hematemesis and rectal bleeding, without lower GI symptoms. Esophagogastroduodenoscopy (EGD) revealed an oesophageal ulcer, while colonoscopy showed no abnormalities. Ulcer histology revealed inflammatory polymorphic infiltrate without vasculitic lesions. Azathioprine, sucralfate and proton pump inhibitor were added to colchicine, and glucocorticoid dose was increased, resulting in clinical improvement.

She remained asymptomatic until 2020, when she developed heartburn and pyrosis. EGD revealed oesophageal ulceration and esophagitis (Figure 1). Biopsies showed oesophageal mucosae with lymphocyte exocytosis and polymorphonuclear cells, with microabscess formation and negative Periodic Acid-Schiff stain; the findings were consistent with chronic esophagitis with signs of activity, in the clinical context of BD. Azathioprine dose was increased to 150 mg/day.

Despite therapy, she developed progressively worsening dysphagia with recurrent episodes of oesophageal food impaction, leading to significant weight loss. The patient also reported fear of eating when alone. EGD could not be concluded due to progressive luminal narrowing and mucosal friability. Barium oesophageal transit study revealed significant stenosis of the proximal oesophagus (Figure 2). Oesophageal dilation was not attempted due to the risk of iatrogenic perforation or haemorrhage in the setting of severely inflamed and friable mucosa.

Given the severity of oesophageal involvement, the patient was therefore proposed for biologic therapy with adalimumab, in collaboration with the gastroenterology team. After one year of anti-tumour necrosis factor therapy, there was no further worsening of the oesophageal stenosis or additional weight loss, and other BD manifestations remained controlled.

## Discussion

BD is a multisystemic variable-vessel vasculitis, with diverse clinical phenotypes, including mucocutaneous lesions, GI and articular involvement, uveitis, arterial aneurysms and vein thrombosis, as well as neurological involvement<sup>1,4,5</sup>.

The disease is endemic in the Mediterranean Basin, Middle East and East Asia, with the highest prevalence in Türkiye, Iran, Saudi Arabia, Iraq, China, and Japan<sup>1,6</sup>. Disease manifestations also vary according to geographic and demographic factors<sup>1</sup>.

The prevalence of GI manifestations is heterogeneous, ranging from 1-4% in Türkiye, India and Saudi Arabia to 60% in United Kingdom and Japan<sup>1,7</sup>. The true prevalence may be underestimated as many patients remain asymptomatic<sup>8,9</sup>.

Regarding GI involvement, ulcers are the most common finding in BD and can be found in any part along the GI tract<sup>6</sup>. Intestinal involvement is more frequent, particularly affecting the ileocecal region<sup>2,8,10</sup>, whereas oesophageal lesions are rarely reported<sup>2,10</sup>. Described manifestations include ulceration, esophagitis, stenosis and perforation<sup>2,3,7-10</sup>.

Our patient developed recurrent oesophageal ulceration and esophagitis that progressed to proximal oesophageal stenosis, leading to severe dysphagia, recurrent food impaction, and significant weight loss. This case highlights the morbidity associated with oesophageal BD.

Although routine endoscopy is not recommended in patients with BD, upper endoscopy should be performed if clinically indicated. Endoscopic evaluation, however, can be technically challenging in the presence of severe inflammatory ulcers and mucosal friability, as demonstrated in this case. Moreover, oesophageal dilatation carries a high risk of perforation or haemorrhage, making medical therapy the cornerstone of management.

A PubMed search (last accessed September 2025) using the terms “Behçet’s disease” AND “oesophageal involvement” was performed to identify published case reports. No additional databases or grey literature sources were systematically searched, given the narrative and case-based nature of this review. Many of these reports corresponded to variceal bleeding secondary to vascular BD rather than primary inflammatory lesions. To date, approximately 40-50 cases of true oesophageal ulceration, esophagitis, or stenosis attributable to BD have been described, as summarized in Table I (representative references shown: <sup>3,11-18</sup>). Several case reports indexed in PubMed lacked available abstracts or full text, which precluded extraction of clinical details; however, they reinforce the rarity of oesophageal BD. Our case therefore adds to the very limited body of evidence on this manifestation.

Pharmacological management is based on the 2018 European Alliance of Associations for Rheumatology (EULAR) recommendations<sup>5</sup>. First-line options for mild mucocutaneous and articular involvement include topical and low-dose glucocorticoids and colchicine<sup>5</sup>. High-dose intravenous corticosteroids and conventional or biological disease-modifying anti-rheumatic drugs (DMARDs), such as azathioprine, cyclophosphamide, ciclosporin and tumour necrosis factor inhibitors (TNFi), are used to treat moderate to severe involvements<sup>1,4,5</sup>. Azathioprine and mesalazine have been the main agents used to treat severe gastrointestinal BD, but TNFi and other biologic DMARDs (e.g. ustekinumab and baricitinib) are increasingly being recognized as effective options in refractory cases<sup>1,5,7,19</sup>. In our patient, despite optimized therapy with azathioprine and glucocorticoids, oesophageal involvement progressed to clinically significant stenosis. The introduction of adalimumab stabilized the oesophageal involvement and controlled the other systemic manifestations, supporting the growing evidence for TNFi in difficult-to-treat BD.

Despite the limited number of cases reported, BD should be considered in patients reporting upper GI symptoms such as pyrosis and dysphagia. Early recognition is essential to avoid major complications, organ damage and impaired quality of life, as seen in our patient. In the absence of standardized guidelines for oesophageal BD, treatment must be individualized and is often extrapolated from intestinal BD. Our experience further supports the potential role of TNFi as a safe and effective therapeutic option in refractory oesophageal BD.

## Conclusion

Oesophageal involvement in Behçet’s disease is rare but may cause severe morbidity. This case highlights the importance of prompt recognition and management of upper GI symptoms in BD, as well as the challenges posed by severe stenosis. Our report adds to the limited literature and supports the potential role of TNF inhibitors in refractory cases.

## Tables and Figures

Author, Year	Age (years)	Sex	Country	Oesophageal involvement	Onset (relation to diagnosis of BD)	Treatment	Outcome
<b>Lebwohl O. et al., 1977</b>	16	F	-	Oesophageal ulcers	5 yrs	GCs	Improved
<b>Wlymen W. J. et al., 1981</b>	12	F	USA	Oesophageal stenosis	1 yr	GCs, surgery	
	14	F	USA	Oesophageal ulcers	1yr	GCs	Improved
<b>Schmutz et al., 1981</b>	-	M	France	Esophagogastric junction ulcers, terminal ileitis	-	-	-
<b>Yasuda Y. et al., 1982</b>	-	-	Japan	Oesophageal involvement (title only)	-	-	-
<b>Griffin JW Jr. et al., 1982</b>	40	M	-	Oesophageal/intestinal ulcers	-	Surgery	Death (related to intestinal involvement)
<b>Mori S. et al., 1983</b>	5 cases	-	-	Oesophageal erosions, ulcers and stenosis	-	-	-
<b>Anti M. et al., 1986</b>	2 cases	-	-	Oesophageal/intestinal ulcers	-	GCs	Improved
<b>Kikuchi et al., 1982</b>	64	M	Japan	Oesophageal/intestinal ulcers	At diagnosis	GCs	Healing
<b>Khatiri et al., 1987</b>	-	-	Libya	Oesophageal ulcers	-	GCs, CYC	Healing
<b>Ozenç et al., 1990</b>	43	M	Turkey	Oesophageal and duodenal ulcers	-	-	-
<b>Lorenzetti et al., 1990</b>	-	F	Australia	Oesophageal/intestinal ulcers	-	-	-
<b>Martínez et al., 1992</b>	-	F	Spain	Oesophageal ulcers	-	GCs, colchicine	Healing
<b>Bottomley et al., 1992</b>	54	F	UK	Oesophageal ulcers and stenosis	-	-	-
<b>Habior et al., 1993</b>	22	M	Poland	Oesophageal/intestinal ulcers	-	-	Several bleeding episodes
<b>Oose et al., 1995</b>	50	F	Japan	Oesophageal stenosis	20 yrs	GCs, surgery	Healing
<b>Ikezawa et al., 1998</b>	30	F	Japan	Oesophageal ulcers	At diagnosis	5-ASA, GCs	Healing
<b>Sonta et al., 2000</b>	19	F	Japan	Oesophageal/intestinal ulcers	-	5-ASA, GCs	
<b>Glosemeyer et al., 2001</b>	39	M	Germany	Oesophageal/intestinal ulcers	6 yrs	GCs, AZA, 5-ASA	Resolved
<b>Yasuo et al., 2003</b>	59	M	Japan	Oesophageal/intestinal ulcers	6 yrs	GCs	Healing

<i>Morimoto et al., 2005</i>	62	M	Japan	Oesophageal ulcer with oesophagobronchial fistula/intestinal ulcers	30 yrs after	GCs	Healing
<i>Fujiwara et al., 2006</i>	38	M	Japan	Oesophageal/intestinal ulcers	At diagnosis	GCs, 5-ASA	Healing
<i>Shin et al., 2009</i>	55	M	Korea	Oesophageal/intestinal ulcers	–	–	–
<i>Yi et al., 2009</i>	32-53	2 M, 4 F	Korea	Oesophageal ulcers	0-9 yrs	GCs, colchicine, AZA 5-ASA	Resolved in 3, improved in 3
<i>Kaneko et al., 2010</i>	18	M	Japan	Oesophageal/intestinal ulcers	8 yrs	GCs, IFX	Improved
<i>Wang et al., 2014</i>	47	M	China	Oesophageal/intestinal ulcers	At diagnosis	Surgery, GCs, thalidomide	Healing
<i>Jia et al., 2017</i>	56	M	China	Oesophageal ulcers	At diagnosis	GCs	Healing
<i>Taniguchi et al., 2020</i>	45	F	Japan	Oesophageal/intestinal ulcers	At diagnosis	GCs	Healing
<i>Murakami K. et al., 2024</i>	38-65	3 M, 3F	Japan	Oesophageal ulcers/erosions	At or after diagnosis	GCs, ADA	Resolved in 3, improved in 1
<i>Almoussa et al., 2024</i>	30	M	Syria	Oesophageal stenosis	Before diagnosis	GCs, CYC	Healing
<i>Jun H. et al., 2025</i>	15-47	3 F	Korea	Oesophageal ulcers	-	GCs, colchicine, AZA	
<i>Present case, 2025</i>	67	F	Portugal	Oesophageal ulcers and stenosis	5 yrs after	Colchicine, GCs, AZA → ADA	No further progression

Table I. Reported cases of oesophageal involvement in Behçet’s disease, extracted from published case reports [representative references shown: [3,11–16]]. A complete list of references is available upon request. ADA – adalimumab, AZA – azathioprine, BD – Behçet disease, CYC – cyclophosphamide, F – female, GCs – glucocorticoids, IFX – infliximab, M – male, UK – United Kingdom, USA – United States of America, 5-ASA – 5-aminosalicylic acid.

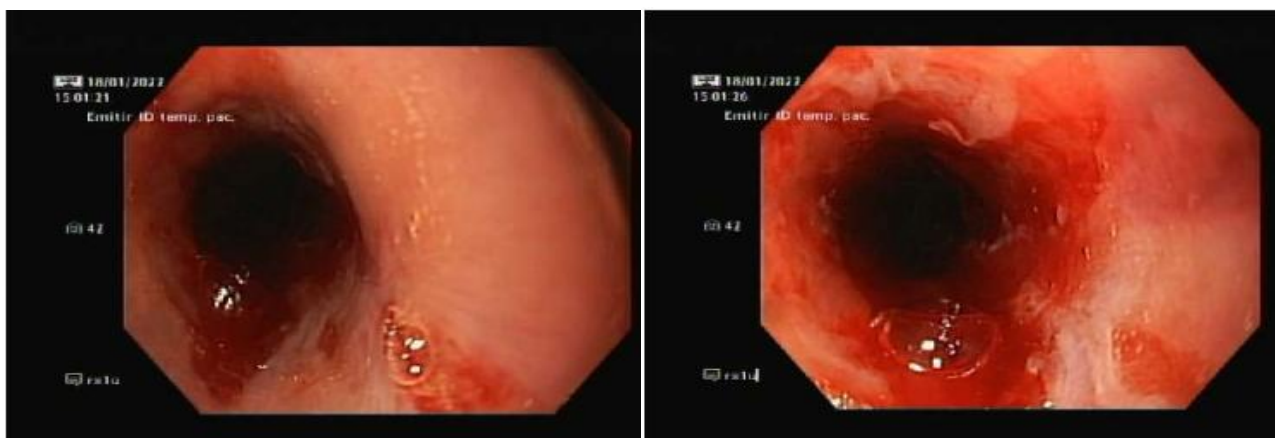


Figure 1. Oesophageal ulceration and mucosal friability seen on esophagogastroduodenoscopy.

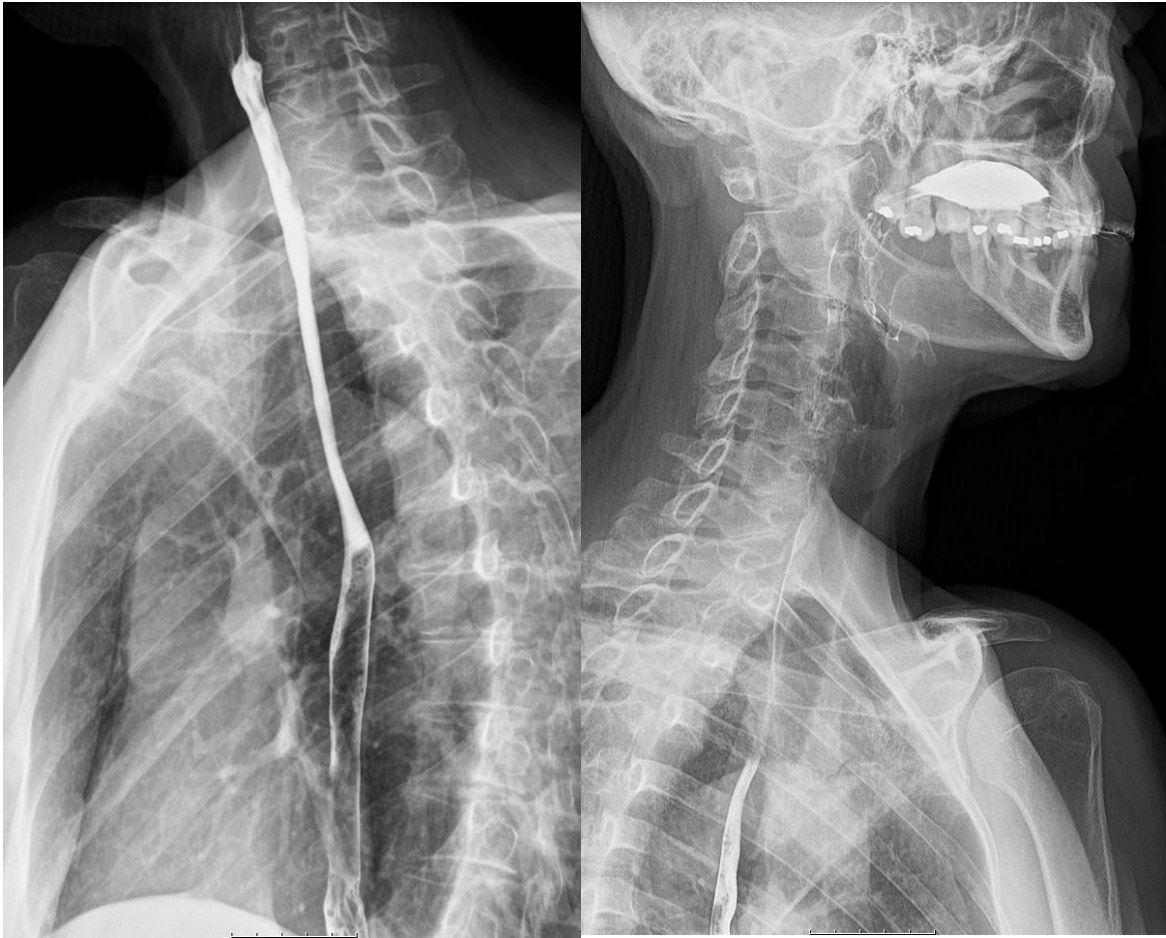

Figure 2. Barium oesophageal transit study showing proximal stenosis.

## References

1. Emmi G, Bettiol A, Hatemi G, Prisco D. Behçet's syndrome. *Lancet* 2024;403:1093-1108.  
[https://doi.org/10.1016/S0140-6736\(23\)02629-6](https://doi.org/10.1016/S0140-6736(23)02629-6)
2. Yi SW, Cheon JH, Kim JH, et al. The prevalence and clinical characteristics of esophageal involvement in patients with Behçet's disease: a single center experience in Korea. *J Korean Med Sci* 2009;24:52-56.  
<https://doi.org/10.3346/jkms.2009.24.1.52>
3. Almousa S, Alhalaki A, Ahmad A, Abdhaleem A, Khazem R. Esophageal stenosis as an initial presentation of Behçet's disease: A case report and literature review. *Egypt Rheumatol* 2024;46:157-160.  
<https://doi.org/10.1016/j.ejr.2024.06.001>
4. Hatemi G, Seyahi E, Fresko I, Talarico R, Uçar D, Hamuryudan V. One year in review 2021: Behçet's syndrome. *Clin Exp Rheumatol* 2021;39:3-13.  
<https://doi.org/10.55563/clinexprheumatol/Invc9k>
5. Hatemi G, Christensen R, Bang D, et al. 2018 Update of the EULAR recommendations for the management of Behçet's syndrome. *Ann Rheum Dis* 2018;77:808-818.  
<https://doi.org/10.1136/annrheumdis-2018-213225>
6. Davatchi F, Chams-Davatchi C, Shams H, et al. Behcet's disease: epidemiology, clinical manifestations, and diagnosis. *Expert Rev Clin Immunol* 2017;13:57-65.  
<https://doi.org/10.1080/1744666X.2016.1205486>
7. Skef W, Hamilton MJ, Arayssi T. Gastrointestinal Behçet's disease: a review. *World J Gastroenterol* 2015;21:3801-3812.  
<https://doi.org/10.3748/wjg.v21.i13.3801>
8. Zou J, Shen Y, Ji DN, et al. Endoscopic findings of gastrointestinal involvement in Chinese patients with Behcet's disease. *World J Gastroenterol* 2014;20:17171-17178.  
<https://doi.org/10.3748/wjg.v20.i45.17171>
9. Park JY, Choi ST, Kim HS. [Esophageal Involvement of Behcet's Disease]. *Korean J Gastroenterol* 2020;76:337-339.  
<https://doi.org/10.4166/kjg.2020.149>
10. Ideguchi H, Suda A, Takeno M, et al. Gastrointestinal manifestations of Behçet's disease in Japan: A study of 43 patients. *Rheumatol Int* 2014;34:851-856.  
<https://doi.org/10.1007/s00296-013-2838-5>
11. Taniguchi Y, Nojima S, Nishiyama M, Terada Y. Esophageal Aphthae and Ulcers Due to Behçet Disease as Cause of Neck and Precordial Chest Pain. *J Clin Rheumatol* 2020;26:e33.  
<https://doi.org/10.1097/RHU.0000000000000821>

12. Oose T, Tokutomi K, Takeuchi A, et al. [A case of Behçet's disease with severe esophageal stenosis treated with esophageal bujie].
13. Lebwohl O, Forde KA, Berdon WE, Morrison S, Challop R. Ulcerative esophagitis and colitis in a pediatric patient with Behcet's syndrome. Response to steroid therapy. *Am J Gastroenterol* 1977;68:550-555.
14. Jia N, Tang Y, Liu H, Li Y, Liu S, Liu L. Rare esophageal ulcers related to Behçet disease: A case report. *Medicine* 2017;96:e8469.  
<https://doi.org/10.1097/MD.0000000000008469>
15. Bottomley WW, Dakkak M, Walton S, Bennett JR. Esophageal involvement in Behçet's disease. Is endoscopy necessary? *Dig Dis Sci* 1992;37:594-597.  
<https://doi.org/10.1007/BF01307585>
16. Kaneko U, Kishi T, Kikuchi M, et al. [Two patients with childhood-onset Behcet's disease successfully treated by anti-tumor necrosis factor therapy]. *Nihon Rinsho Meneki Gakkai Kaishi* 2010;33:157-161.  
<https://doi.org/10.2177/jsci.33.157>
17. Jun H, Song HJ, Mun JH, et al. [Upper Gastrointestinal Involvement in Behcet's Disease]. *Korean J Gastroenterol* 2025;85:170-178.  
<https://doi.org/10.4166/kjg.2024.148>
18. Murakami K, Arai J, Ihara S, et al. Upper gastrointestinal involvement of Behçet's disease in Japan: endoscopic findings and clinical features. *J Gastroenterol Hepatol* 2024;39:708-715.  
<https://doi.org/10.1111/jgh.16479>
19. Hisamatsu T, Hayashida M. Treatment and outcomes: Medical and surgical treatment for intestinal Behçet's disease. *Intest Res* 2017;15:318-327.  
<https://doi.org/10.5217/ir.2017.15.3.318>