

Reversed halo sign: an uncommon presentation of pediatric eosinophilic granulomatosis with polyangiitis

Silva L¹, Jesus AR², Gata L³, Ferreira S⁴, Basso S⁵, Estanqueiro P⁶, Nascimento J⁷, Salgado M⁸

¹ Pediatric Rheumatology Unit, Hospital Pediátrico - Centro Hospitalar Universitário de Coimbra
- ORCID: <https://orcid.org/0000-0002-0316-6167>

² Emergency Department, Hospital Pediátrico - Centro Hospitalar Universitário de Coimbra -
ORCID: <https://orcid.org/0000-0002-2649-5430>

³ Emergency Department, Hospital Pediátrico - Centro Hospitalar Universitário de Coimbra

⁴ Pneumology Unit, Hospital Pediátrico - Centro Hospitalar Universitário de Coimbra

⁵ Radiology Department, Hospital Pediátrico - Centro Hospitalar Universitário de Coimbra

⁶ Pediatric Rheumatology Unit, Hospital Pediátrico - Centro Hospitalar Universitário de Coimbra
- ORCID: <https://orcid.org/0000-0003-2778-7643>

⁷ Pediatric Rheumatology Unit, Hospital Pediátrico - Centro Hospitalar Universitário de Coimbra
- ORCID: <https://orcid.org/0000-0002-8503-4466>

⁸ Pediatric Rheumatology Unit, Hospital Pediátrico - Centro Hospitalar Universitário de Coimbra

Correspondence to

Luana Silva

E-mail: luanamarisa@gmail.com

Submitted: 14/08/2022

Accepted: 03/10/2022

This article has been accepted for publication and undergone full peer review but has not been through the copyediting, typesetting, pagination and proofreading process which may lead to differences between this version and the Version of Record. Please cite this article as an 'Accepted Article'

© 2022 Portuguese Society of Rheumatology

This article is protected by copyright. All rights reserved.

CASE REPORT

A 12-year-old girl presented at the Emergency Department with dyspnea and a two-day pleuritic left chest stabbing pain, without fever. She reported weight loss (6% of total body weight) and recurrent back pain over the previous two months. Personal and familiar health history and physical examination were unremarkable. Blood analysis, aside eosinophilia ($1060 \times 10^9/\text{liter}$), was normal (erythrocyte sedimentation rate - 10 mm/1st hour and C-reactive protein - 0,12 mg/dl). Chest radiograph showed a cavitory lung opacity in the left lung (Figure 1). A chest computed tomography (chest-CT) performed in the following day, confirmed the presence of two cavitory lung opacities, also known as reversed halo sign, in the left lung (Figure 2, 3 and 4).

Initial etiologic investigation was negative. Serologies for *Aspergillus fumigatus*, *Chlamydophila psitacci*, *Echinococcus* species and Human Immunodeficiency Virus were negative as were Interferon Gamma Release Assay, tuberculin test, SARS-CoV-2 protein chain reaction, antinuclear antibodies, anti-neutrophil cytoplasmic antibody (ANCA)-(anti-myeloperoxidase, anti-proteinase 3) and serum angiotensin-converting enzyme. She had an isolated elevation of immunoglobulin E (5509 U/ml), with normal complement and lymphocyte subpopulation. Urinalysis was normal. An unrevealing abdominal ultrasound and bone scintigraphy were performed. Otorhinolaryngology evaluation revealed seasonal rhinitis. Non-steroidal anti-inflammatory drugs and paracetamol were initiated for pain management. No other treatment was administered.

One month after presentation, a chest-CT guided pulmonary biopsy was performed, showing microscopic nodular lesions in capillaries and arterioles and intra-alveolar desquamation, with a predominance of macrophages and eosinophils, consistent with eosinophilic granulomatosis with polyangiitis (EGPA).

Cardiac evaluation and pulmonary function tests were normal. Oral prednisolone (0,5 mg/kg/day) and azathioprine (1 mg/kg/day) were initiated. She had transient chest pain at month two of treatment with worsening of eosinophilia ($1.4 \times 10^9/\text{liter}$). At month six of treatment, she was asymptomatic, under low dose prednisolone (5 mg/48 hours) and azathioprine (1 mg/kg/day) and had a normal chest radiograph.

DISCUSSION

EGPA, also known as Churg-Strauss Syndrome, is an ANCA-associated vasculitis extremely rare in childhood. It presents with constitutional symptoms, asthma, peripheral eosinophilia and peripheral neuropathy¹. Nodules, ground glass and reticular opacities have been described on chest-CT in children with pediatric EGPA². ANCA are positive in 35-40%. Pediatric EGPA has an increased mortality rate, probably associated with higher incidence of cardiomyopathy.¹

The 2022 American College of Rheumatology/Europe Alliance of Associations for Rheumatology classification criteria for EGPA (for patients with a previous diagnosis of small or medium vasculitis) includes clinical (obstructive airway disease, nasal polyps and mononeuritis multiplex) and laboratory and biopsy criteria (blood eosinophil count $\geq 1 \times 10^9$ /liter, extravascular predominant inflammation on biopsy, positive ANCA antibodies and hematuria). A score of ≥ 6 is necessary for classification.³ Our patient had $\geq 1 \times 10^9$ /liter eosinophilia and extravascular inflammation, with a score of 7. Although evidence for management of pediatric EGPA is lacking, glucocorticoids plus azathioprine should be considered as initial therapy for active non-severe EGPA.⁴

Figures

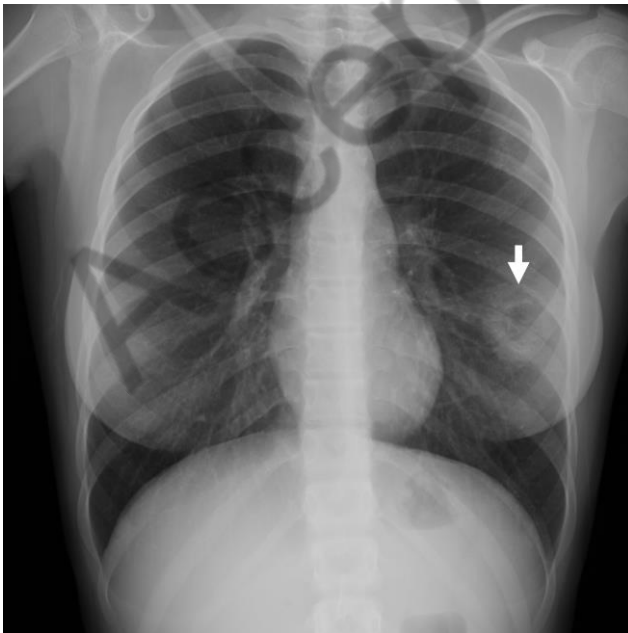


Figure 1: Chest radiograph (anterior posterior) showing reversed halo sign (arrow) in the left lung

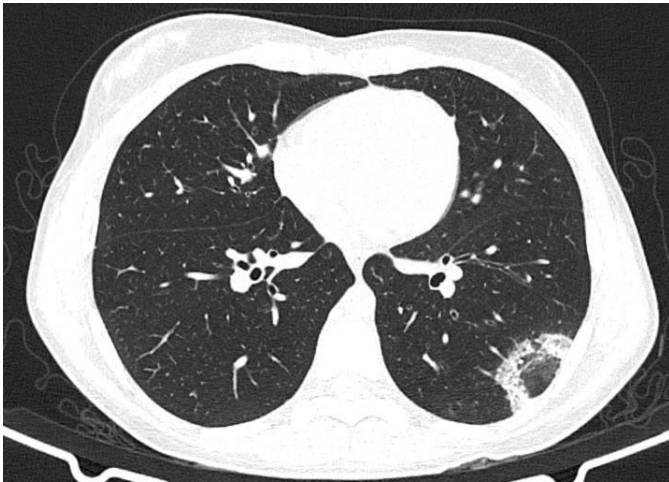

Figure 2: CT-scan (axial plane) showing a subpleural consolidation with a reversed halo sign image (ground glass center with a surrounding consolidation) in the left lower lobe

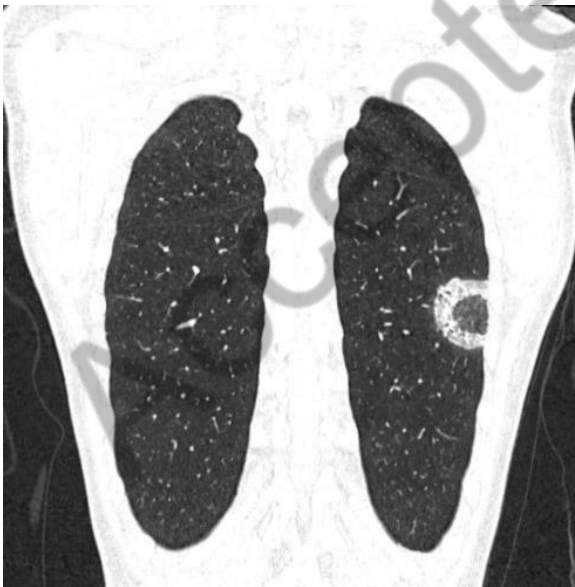

Figure 3: CT-scan (coronal plane) showing a subpleural consolidation with a reversed halo sign image (ground glass center with a surrounding consolidation) in the left lower lobe

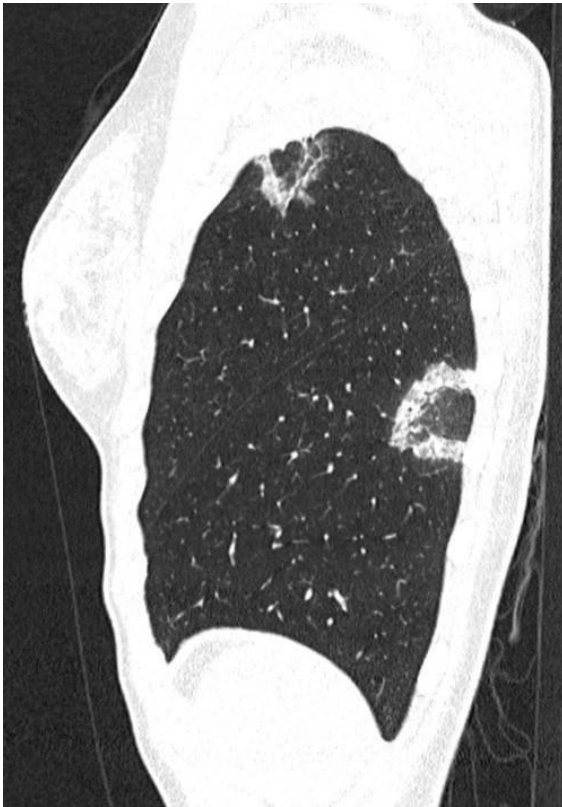

Figure 4: CT-scan (sagittal plane) showing two subpleural consolidation with a reversed halo sign image: 1 in the left superior lobe (31x20 mm) and 1 in the left lower lobe (45x26 mm)

References

1. Calatroni M, Oliva E, Gianfreda D, Gregorini G, Allinovi M, Ramirez GA, et al. ANCA-associated vasculitis in childhood: recent advances. *Ital J Pediatr.* 2017;43(1):46–49. doi: 10.1186/s13052-017-0364-x
2. Fina A, Dubus JC, Tran A, Derelle J, Reix P, Fayon M, et al. Eosinophilic granulomatosis with polyangiitis in children: Data from the French RespiRare® cohort. *Pediatr Pulmonol.* 2018;53(12):1640–50. doi: 10.1002/ppul.24089
3. Grayson PC, Ponte C, Suppiah R, Robson JC, Craven A, Judge A, et al. 2022 American College of Rheumatology / European Alliance of Associations for Rheumatology Classification

Criteria for Eosinophilic Granulomatosis With Polyangiitis. *Arthritis Rheum.* 2022;0(0):1–7. doi: 10.1002/art.41982

4. Chung SA, Langford CA, Maz M, Abril A, Gorelik M, Guyatt G, et al. 2021 American College of Rheumatology / Vasculitis Foundation Guideline for the Management of Antineutrophil Cytoplasmic Antibody – Associated Vasculitis. *Arthritis Care Res.* 2021;73(8):1088–105. doi: 10.1002/acr.24634

5. Georgiadou SP, Sipsas N V, Marom EM, Kontoyiannis DP. The Diagnostic Value of Halo and Reversed Halo Signs for Invasive Mold Infections in Compromised Hosts. *Clin Infect Dis.* 2011;52:1144–55. doi: 10.1093/cid/cir122

Accepted article