

## Vasculitis in cocaine users - not all that glows is gold

Silva A<sup>1</sup>, Martins N<sup>2</sup>, Teixeira V<sup>3</sup>, Saavedra MJ<sup>4</sup>, Romeu JC<sup>4</sup>

<sup>1</sup> Rheumatology, Centro Hospitalar e Universitário Lisboa Norte

ORCID: <https://orcid.org/0000-0003-4064-1198>

<sup>2</sup> Rheumatology, Centro Hospitalar Tondela Viseu

<sup>3</sup> Rheumatology, Centro Hospitalar e Universitário do Algarve

<sup>4</sup> Rheumatology, Centro Hospitalar e Universitário Lisboa Norte

### Correspondence to

Augusto José Serra Gaspar da Silva

E-mail: [augusto.silva@chln.min-saude.pt](mailto:augusto.silva@chln.min-saude.pt)

**Submitted:** 11/02/2023

**Accepted:** 27/04/2023

This article has been accepted for publication and undergone full peer review but has not been through the copyediting, typesetting, pagination and proofreading process which may lead to differences between this version and the Version of Record. Please cite this article as an 'Accepted Article'

© 2023 Portuguese Society of Rheumatology

This article is protected by copyright. All rights reserved.

## Background

Cocaine, one of the most illicit substances consumed in Portugal, may induce cutaneous, mucosal and systemic manifestations. Levamisole, a substance used to adulter cocaine, may be responsible for potential toxic effects<sup>1</sup>. Despite the absence of studies in Portugal, data from other European countries revealed that the percentage of cocaine contaminated by levamisole oscillated between 6 to 85%, from 2005 to 2013, while in the United States of America (USA) it was around 70% in 2009. The panorama seems to be changing, with a downward trend of around 40% in European countries and 22% in the USA by 2020<sup>1,2,3</sup>. Vasculitic syndromes induced by cocaine can be related to local effects of the drug itself or attributed to the contaminant levamisole<sup>1,4</sup>. The typical cutaneous disease presents as leukocytoclastic vasculitis and/or thrombotic vasculopathy<sup>5</sup>.

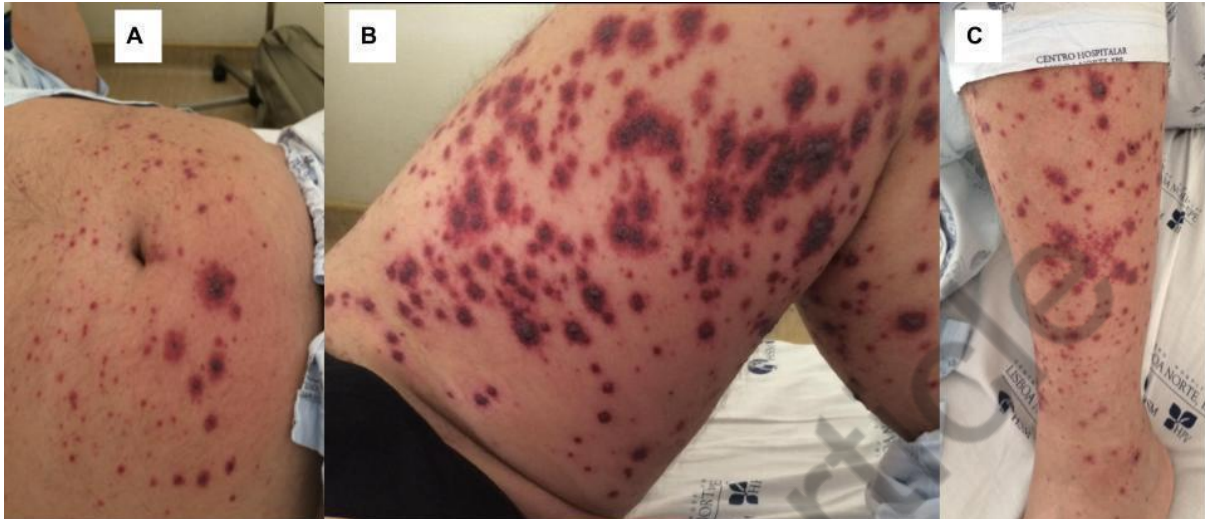
**Case 1:** A 49-year-old male, presented with one day history of erythematous-purpuric and necrotic rash on both legs (Figure 1), after using cocaine from a supplier different from the usual one. The lesions progressed to the lower abdominal, dorsal region and upper limbs within one day. He denied fever, arthralgia, abdominal pain, gastrointestinal bleeding and haematuria. He had a medical background history of gout arthritis, ruptured pancreato-duodenal artery aneurysm, heavy alcohol and cocaine consumption for the last 30 years. He took only colchicine on demand. Laboratory tests revealed C-reactive protein (CRP) of 2.6 mg/dL, absence of levamisole in the cocaine sample, with no other changes. He refused therapy but there was spontaneous improvement of the lesions and he was discharged three days after admission. He continued the cocaine and alcohol consumption and one week later returned to the hospital due to worsening of the lesions. He was commenced on prednisolone 60 mg daily with irregular compliance, but rapid improvement. The skin biopsy revealed leukocytoclastic vasculitis with intraluminal thrombus (Figure 2). Immunofluorescence revealed linear IgG, IgA and complement deposits along the basement membrane and vessel wall of the papillary dermis, with no IgM deposits. These abnormalities are commonly seen in cocaine-related vasculitis. After two months he did not require treatment and one year later he remained asymptomatic, despite maintaining cocaine consumption.

**Case 2:** A 34-year-old healthy male, presented to the emergency department with ten days history of progressive erythematous-purpuric rash on both legs (Figure 3) and six days of knee and ankle oligoarthritis, after cocaine consumption from a different supplier on the night

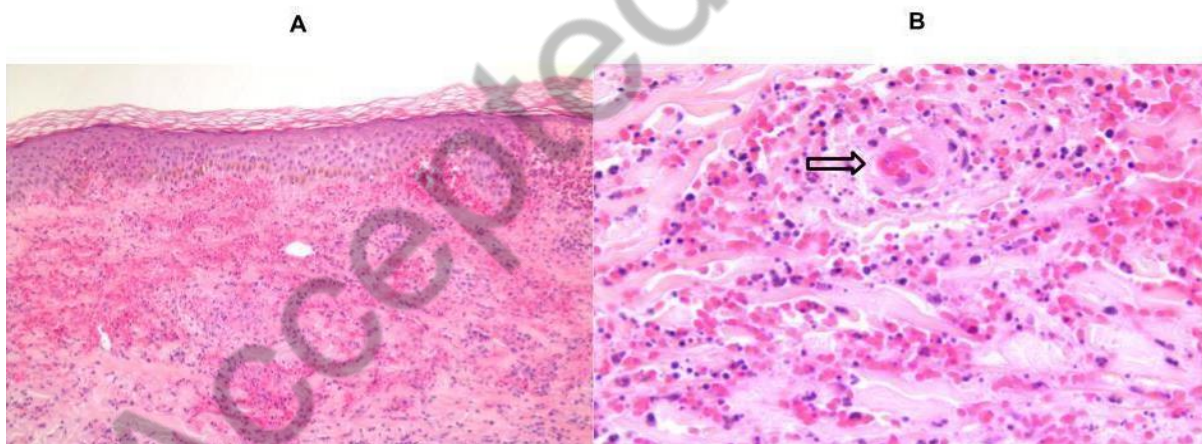
before the complaints started. He was initially seen in the emergency department of a different hospital about seven days after the onset of symptoms, but was discharged without any medication. He denied fever, abdominal pain, gastrointestinal bleeding and haematuria. Regarding his medical history, he reported occasional cocaine consumption in the last two years. Laboratory tests revealed a CRP of 5.45 mg/dL, without other changes. Due to the absence of a cocaine sample, the presence of levamisole was not tested. He was admitted, a skin biopsy was performed by dermatology and 60 mg of prednisolone daily was started. Four days later, the rash and arthritis practically disappeared, CRP decreased to 1.36 mg/dL, and he was discharged. After one month, with 40 mg of prednisolone daily, he had recurrence of new lesions on the legs and buttocks. Skin biopsy revealed leukocytoclastic vasculitis of the superficial and middle dermis, presence of neutrophilic hidradenitis and no thrombotic vasculopathy (Figure 4), with negative direct immunofluorescence, which was fundamental for the diagnosis of neutrophilic urticarial vasculitis. The patient was started on colchicine 1 mg daily and methotrexate 15 mg weekly, with reduction of prednisolone and complete clinical and laboratory remission. After one year of follow-up he remains asymptomatic without cocaine consumption.

**Conclusion:** Two distinct vasculitis cases in cocaine consumers were described. Cocaine consumption is associated with vasculitis, however at presentation the differential diagnosis is wide. A complete medical history and physical examination is useful, but skin biopsy is essential for diagnosis confirmation. Since both patients were chronic consumers of cocaine, but only developed vasculitis after a change in the supplier, this may suggest that cocaine adulterants may also play a role in inducing vasculitis either directly or by promoting specific cocaine vasculitis mechanisms.

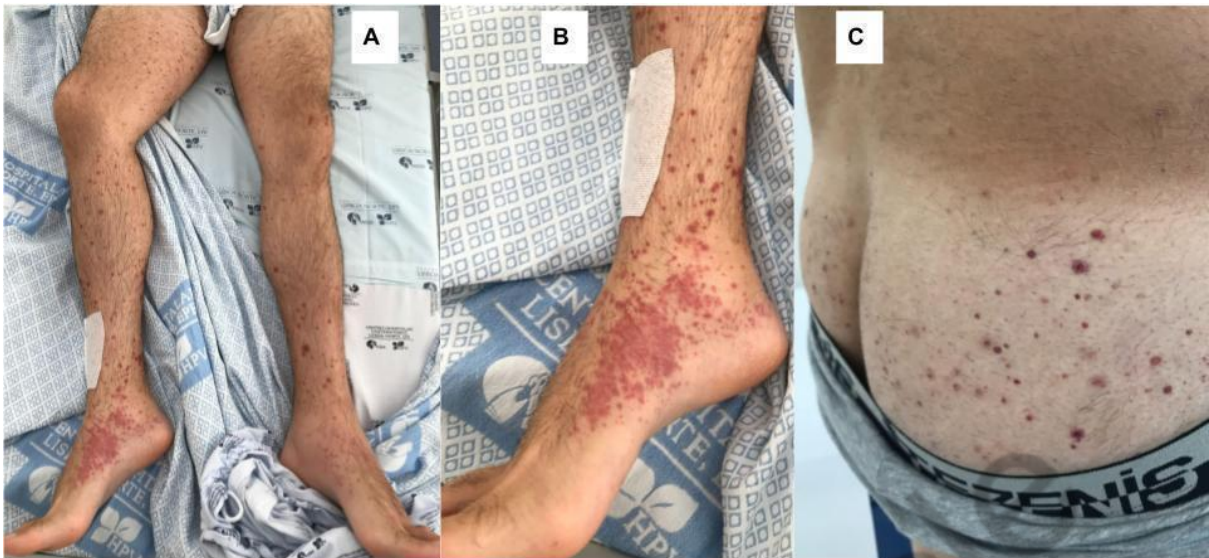**Figures**



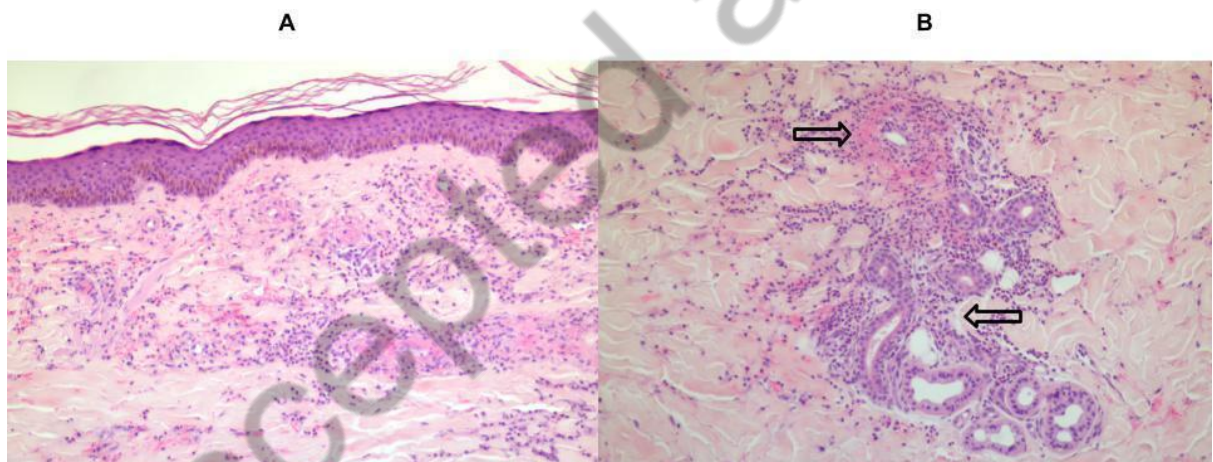
**Figure 1** - Erythematous-purpuric and necrotic rash on lower abdominal wall (A), inner side of the lower left limb (B) and anterior region of the left leg (C).



**Figure 2 (hematoxylin and eosin stains):** **A** - Skin biopsy from left leg (x100). Exuberant extravasation of erythrocytes, in the upper and middle dermis, with permeation of the epidermis. Perivascular and interstitial inflammatory infiltrate of lymphocytes, histiocytes and numerous neutrophils. **B** - Skin biopsy from the left leg (x400). Fibrin deposits on the wall of a vessel of the upper dermis, with an intraluminal thrombus (arrow), surrounded by inflammatory infiltrate with intense leukocytoclasia and numerous erythrocytes.



**Figure 3** - Erythematous-purpuric and necrotic rash on the legs (A), inner side of the right foot (B) and buttocks (C).



**Figure 4 (hematoxylin and eosin stains): A** - Skin biopsy from the left leg (x100). Fibrin deposits on the wall of most vessels of the upper and middle dermis, with no intravascular thrombus. Perivascular and interstitial inflammatory infiltrate in the dermis, composed of lymphocytes, histiocytes and neutrophils, with extravasation of erythrocytes. **B** - Skin biopsy from the left leg (x100). Leukocytoclastic vasculitis: vessel wall destruction with fibrin deposits, surrounded by inflammatory infiltrate with significant leukocytoclasia (upper arrow). Neutrophilic adenitis: inflammatory neutrophilic infiltrate involving an eccrine sweat gland with rare eosinophils (bottom arrow).

## References

1. Serviço de Intervenção nos Comportamentos Aditivos e nas Dependências: Direção de Serviços de Monitorização e Informação/Divisão de Estatística e Investigação. Relatório Anual - 2018 - A Situação do País em Matéria de Drogas e Toxicodependências, 2019.
2. Eiden C, Diot C, Mathieu O, Mallaret M, Peyrière H. Levamisole-adulterated cocaine: what about in European countries? *J Psychoactive Drugs*. 2014 Nov-Dec;46(5):389-92.
3. [https://www.emcdda.europa.eu/publications/eu-drug-markets/cocaine/retail-markets\\_en](https://www.emcdda.europa.eu/publications/eu-drug-markets/cocaine/retail-markets_en)
4. Berman M, Paran D, Elkayam O. Cocaine-Induced Vasculitis. *Rambam Maimonides Med J*. 2016 Oct 31;7(4):e0036. doi: 10.5041/RMMJ.10263.
5. Imbernón-Moya A, Chico R, Aguilar-Martínez A. Cutaneous and mucosal manifestations associated with cocaine use. *Med Clin (Barc)*. 2016 Jun 17;146(12):544-9. Spanish. doi: 10.1016/j.medcli.2016.02.015.

Accepted article