ARP Rheumatology 2026;5:194-199
https://doi.org/10.63032/HVBX8756

CASE BASED REVIEWS

X-linked hypophosphataemia diagnosed in adulthood with coexisting seronegative rheumatoid arthritis: a diagnostic pitfall

Moniz AC[1,2], Patrocínio Gomes M[3], Santos ME[1,2], Cacheira E[3], Mateus M[4], Costa M[1,2], Sepriano A[1,2]

ABSTRACT

Introduction: X-linked hypophosphataemia (XLH) is the most common inherited cause of renal phosphate wasting, typically diagnosed in childhood but occasionally identified in adulthood.
Case report: We report a case of a 45-year-old woman with long-standing lower limb deformities, short stature, and diffuse joint pain. Laboratory evaluation revealed hypophosphataemia due to isolated renal phosphate wasting. Fibroblast growth factor 23 levels were markedly elevated. Imaging showed skeletal deformities and enthesopathic changes consistent with chronic XLH. Genetic testing identified a pathogenic PHEX variant (c.1645+1G>A), confirming the diagnosis. Treatment with oral phosphate and calcitriol resulted in biochemical improvement. During follow-up, the patient developed symmetrical erosive polyarthritis of the hands and wrists, consistent with seronegative rheumatoid arthritis superimposed on the underlying metabolic disorder.
Discussion: This case highlights the diagnostic challenge of XLH in adults, where musculoskeletal manifestations can closely mimic inflammatory arthritis. Recognising XLH as the underlying cause of chronic osteomalacia is essential to avoid inappropriate treatment and ensure timely management of coexisting conditions. New-onset erosive arthritis should prompt consideration of a concurrent inflammatory condition rather than attribution to the underlying metabolic disorder.

Keywords: X-linked hypophosphataemia; Osteomalacia; Renal phosphate wasting; Enthesopathy; Rheumatoid arthritis; Delayed diagnosis.

INTRODUCTION

X-linked hypophosphataemia (XLH) is the most common inherited cause of renal phosphate wasting, resulting from pathogenic variants in the PHEX gene with consequent fibroblast growth factor 23 excess and impaired renal phosphate reabsorption. Classical manifestations include rickets, skeletal deformities, short stature, dental disease and osteomalacia[1].

Although XLH is usually diagnosed in childhood, adult diagnosis occurs, particularly in patients with attenuated disease, absent family history or limited access to metabolic evaluation[1,2]. We report a woman with childhood-onset skeletal abnormalities in whom XLH was diagnosed only in adulthood, complicated by the subsequent development of erosive seronegative rheumatoid arthritis, highlighting the diagnostic challenge of distinguishing metabolic bone disease from superimposed inflammatory arthritis.

[1] Rheumatology Department, Hospital de Egas Moniz, Unidade Local de Saúde de Lisboa Ocidental, Lisboa, Portugal
[2] NOVA Medical School, Universidade Nova de Lisboa, Lisboa, Portugal
[3] Nephrology Department, Hospital de Santa Cruz, Unidade Local de Saúde de Lisboa Ocidental, Lisboa, Portugal
[4] Rheumatology Department, Centro de Ortopedia e Musculoesquelético, Hospital Cuf Tejo, Lisboa, Portugal

Submitted: 26/05/2026
Accepted: 24/07/2026
Correspondence to: Ana Catarina Moniz
E-mail: acmoniz040@gmail.com

CASE REPORT

We report the case of a 45-year-old woman referred to the rheumatology clinic for diffuse joint pain, predominantly involving the knees. Her medical history was notable for progressive varus deformity of the lower limbs since the age of two, requiring two corrective orthopaedic surgeries during childhood, with subsequent valgus realignment. She also reported frequent dental caries and mobility of the lower anterior teeth. She had no history of fractures, trauma, joint infection, connective tissue disease, or family history of metabolic bone disorders. The chronological sequence of the patient's clinical course is summarised in Figure 1.

Physical examination revealed short stature, limb shortening, and bowing of the humeri, femurs, and tibiae, with valgus alignment of the knees. Range of motion was reduced in the shoulders, elbows, hips, and knees, with fixed flexion of approximately 20° in both

(C) 2026 Sociedade Portuguesa de Reumatologia. This is an open access article under the CC BY-NC-ND license.

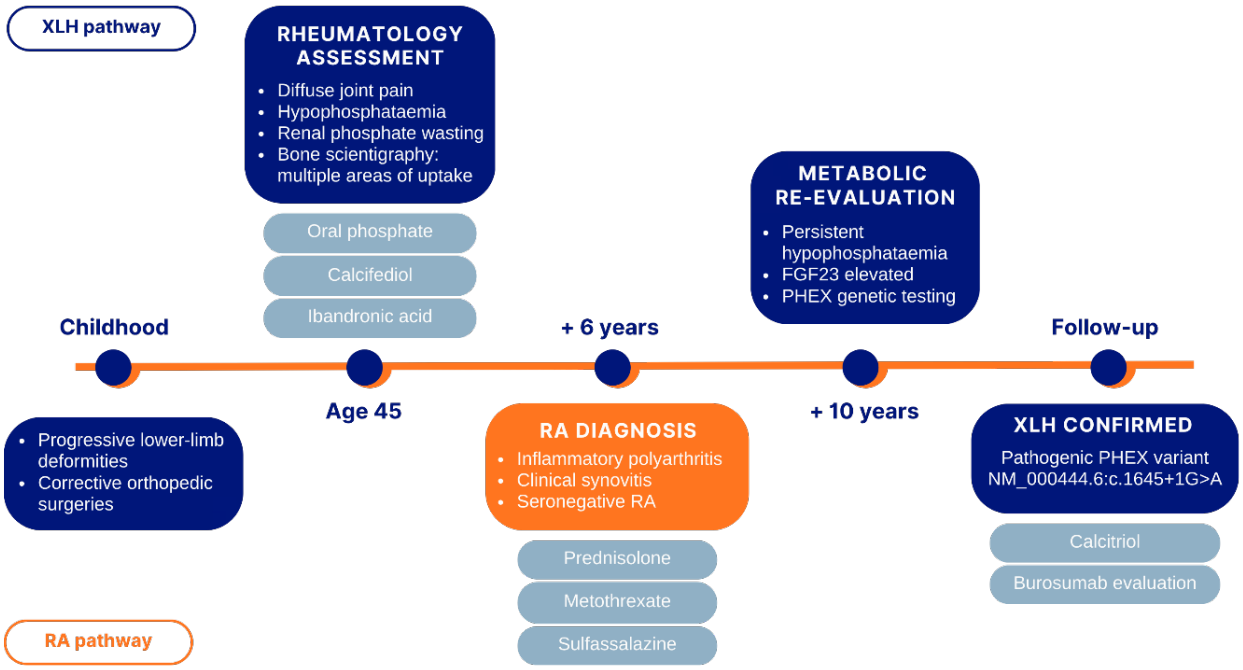

Figure 1. Timeline summarising the patient's clinical course, including the diagnostic evaluation and management of X-linked hypophosphataemia and subsequent seronegative rheumatoid arthritis. FGF23, Fibroblast growth factor 23; PHEX, Phosphate-regulating endopeptidase homolog X-linked; RA, Rheumatoid arthritis; XLH, X-linked hypophosphataemia.

elbows and knees. No active arthritis, lymphadenopathy, or organomegaly was observed. Vital signs were within normal limits.

Baseline laboratory evaluation (Table I) demonstrated hypophosphataemia (1.7 mg/dL), low-normal serum calcium (8.8 mg/dL) and low 25-hydroxyvitamin D (25[OH]D 39.3 nmol/L). Parathyroid hormone (PTH) was mildly elevated (82 pg/mL), in the absence of hypocalcaemia or renal insufficiency. Total alkaline phosphatase (ALP), magnesium, serum creatinine, and urea were within normal ranges. Urinary calcium excretion was low (41 mg/24h). Despite hypophosphataemia, urinary phosphate excretion remained inappropriately preserved at 558.9 mg/24h, with a fractional excretion of phosphate ($FEPO_4$) of 16.9%, indicating impaired renal phosphate conservation. Tubular maximum phosphate reabsorption per glomerular filtration rate (TmP/GFR) was reduced at 1.62 mg/dL, confirming inappropriate renal phosphate wasting.

Conventional radiographs revealed diffuse skeletal deformities, including bowing of the humeri, femurs, and tibiae, widening of the distal radial and ulnar epiphyses, valgus alignment of the knees, and radiographic signs of secondary osteoarthritis (Figure 2). Prominent enthesopathic changes were observed at the patellar, triceps, and Achilles tendon insertions. Bone scintigraphy revealed multiple areas of increased tracer uptake involving the right seventh rib, right carpus, right tarsus, both femurs, and the sacrum, suggestive of insufficiency fractures. Dual-energy X-ray absorpti-

TABLE I. Initial laboratory evaluation of the patient

Laboratory parameter	Result	Reference range
Serum		
Creatinine	0.53	0.5 – 0.9 mg/dL
Phosphate	1.7	2.5 – 4.5 mg/dL
Calcium	8.8	8.6 – 10 mg/dL
Magnesium	1.9	1.6 – 2.6 mg/dL
25(OH)D	39.3	75 – 250 nmol/L
PTH	82	15 – 65 pg/mL
ALP	72	35 – 104 U/L
Urine		
Calcium	41	100 – 300 mg/24 h
Phosphate	558.9	400 – 1300 mg/24 h
$FEPO_4$	16.9	%
TmP/GFR	1.62	2.6 – 3.8 mg/dL

Values shown include baseline serum and urine measurements. 25(OH)D, 25-hydroxyvitamin D; PTH, parathyroid hormone; ALP, alkaline phosphatase; FEPO4, fractional excretion of phosphate; TmP/GFR, tubular maximum phosphate reabsorption per glomerular filtration rate.

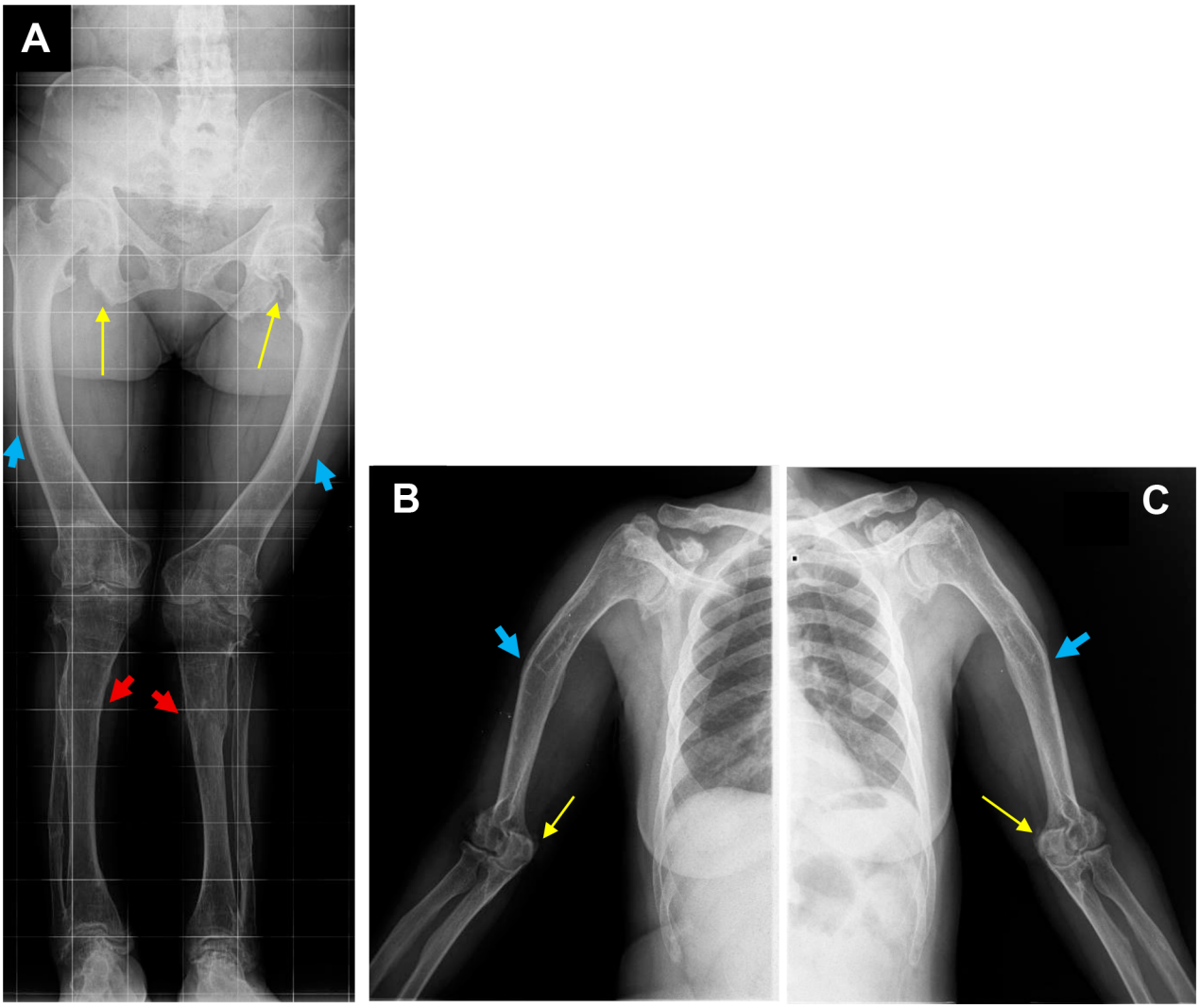

Figure 2. Radiographic features of long bone deformities in the reported patient.
(A) Standing full-length lower-limb radiograph showing bilateral femoral and tibial bowing with mild valgus alignment of the knees. (B–C) Anteroposterior shoulder radiographs showing bowing of the humeral shafts. Blue arrows indicate characteristic skeletal deformities, yellow arrows indicate enthesopathic changes, and red arrows indicate areas of tibial realignment following previous corrective surgeries.

ometry (DXA) demonstrated lumbar spine bone mineral density above the expected range for age (L1-L3 Z-score +2.8), with marked heterogeneity across vertebral levels (L4 Z-score +3.8), while femoral neck and wrist bone mineral density were near-normal (Z-score –0.3) and mildly reduced (Z-score –1.9), respectively.

Treatment was initiated with oral phosphate (monosodium phosphate titrated to 80 mmol/day), 25(OH)D (calcifediol, 0.266 mg biweekly), and calcium carbonate (1500 mg/day). Ibandronic acid (150 mg monthly) was also prescribed based on scintigraphic evidence of multiple insufficiency fractures, before osteomalacia was recognised as the unifying diagnosis. During follow-up, 25(OH)D and PTH levels normalised, but serum phosphate levels fluctuated over time, requiring progressive dose escalation to maintain levels within the normal range.

Six years after the first rheumatology assessment, the patient developed new inflammatory polyarthralgia involving the wrists and hands. Clinical synovitis was confirmed in the metacarpophalangeal (MCP) and proximal interphalangeal (PIP) joints. Laboratory tests showed mildly elevated C-reactive protein (0.89 mg/dL, reference range [RR] <0.5), normal erythrocyte sedimentation rate (ESR), and negative rheumatoid factor and anti-citrullinated protein antibodies. Hand radiographs demonstrated periarticular osteopenia, diffuse joint-space narrowing predominantly involving the MCP and PIP joints, marginal erosions, ulnar deviation, MCP subluxation and intercarpal joint-space narrow-

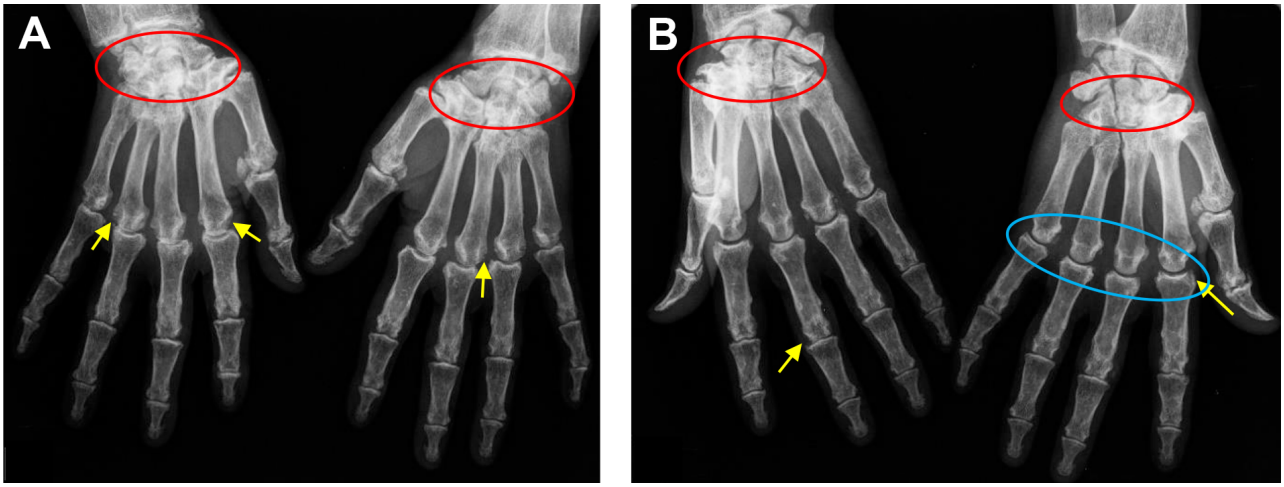

Figure 3. Hand radiographs consistent with seronegative rheumatoid arthritis.
(A) Posteroanterior (PA) view; (B) oblique view. Bilateral periarticular osteopenia, diffuse joint-space narrowing predominantly involving the metacarpophalangeal and proximal interphalangeal joints, marginal erosions (yellow arrows), ulnar deviation with metacarpophalangeal subluxation (blue circle) and intercarpal joint space narrowing (red circles) are present.

ing (Figure 3). No chondrocalcinosis was identified on the available radiographs. These findings, together with the clinical pattern of symmetrical inflammatory polyarthritis, were considered inconsistent with the pre-existing skeletal abnormalities and raised suspicion of a concomitant inflammatory arthropathy. A diagnosis of seronegative rheumatoid arthritis (RA) was made (baseline DAS28-CRP 3.43 – moderate disease activity). Prednisolone 20 mg/day was initiated as bridging therapy, with rapid clinical improvement, followed by oral methotrexate (gradually escalated from 15 mg to 20 mg weekly). Because glucocorticoids could not be tapered below 15 mg/day after six months, sulfasalazine (2 g/day) was added, allowing successful glucocorticoid withdrawal and sustained clinical remission within one year.

Approximately ten years after initial presentation, further metabolic investigation was undertaken, prompted by persistent and fluctuating hypophosphataemia despite high-dose phosphate supplementation. The absence of glycosuria, metabolic acidosis, or hyperuricosuria argued against generalised proximal tubular dysfunction, while the presence of childhood-onset skeletal abnormalities made tumour-induced osteomalacia unlikely. Urinary beta-2 microglobulin was markedly elevated (16 mg/L, RR <0.2), although no other features of generalized proximal tubular dysfunction were identified. Aminoaciduria and 1,25(OH)D were unavailable. FGF23 levels were markedly elevated at 1250 AU/mL (RR <180), consistent with an FGF23-mediated phosphate-wasting disorder. Genetic testing identified a heterozygous PHEX variant (NM_000444.6:c.1645+1G>A, previously reported in ClinVar as pathogenic[3]), establishing the diagnosis of XLH.

Following genetic confirmation, treatment was adjusted to oral phosphate combined with calcitriol (initial dose 1 µg/day, subsequently reduced to 0.5 µg/day), achieving normal phosphate (3.8 mg/dL) and PTH (58.7 pg/mL) levels at six months. Calcium supplementation is being tapered, and the patient is under evaluation for burosumab therapy. Annual renal ultrasonography is planned to monitor for nephrocalcinosis.

DISCUSSION

This case highlights two diagnostic challenges: delayed recognition of XLH in adulthood and the emergence of a superimposed inflammatory arthritis. Together, these illustrate the risk of diagnostic anchoring, whereby new inflammatory symptoms were initially attributed to the underlying metabolic disorder.

In adults, XLH commonly presents with enthesopathy, tendon calcifications, and early-onset osteoarthritis driven by chronic mechanical stress, which may closely overlap with inflammatory arthritis[4,5]. In this patient, the diagnosis was established by the combination of long-standing skeletal deformities, persistent hypophosphataemia with isolated renal phosphate wasting (reduced TmP/GFR without features of generalised tubular dysfunction), markedly elevated FGF23, and a pathogenic PHEX variant. The mild PTH elevation is a recognised feature of XLH, driven by FGF23-mediated suppression of calcitriol synthesis rather than calcium deficiency per se[1]. Retrospectively, the reported

dental caries and tooth mobility were consistent with XLH-associated dental disease, resulting from defective dentine mineralisation and increased susceptibility to periapical abscesses — a recognised but frequently overlooked manifestation of the disease[6]. Although the patient reported multiple dental complications during childhood/adolescence that may support this diagnosis, including recurrent spontaneous dental abscesses, formal dental records confirming these findings were unavailable for review. This is acknowledged as a limitation in unequivocally associating the reported dental manifestations with this diagnosis. The absence of family history did not exclude XLH, given the possibility of *de novo* variants in approximately 20–30% of cases[1] or unrecognised disease in relatives [2]. Empirical phosphate and vitamin D supplementation may have partially masked the biochemical phenotype during follow-up, potentially contributing to delayed aetiological clarification.

Differentiating XLH-related musculoskeletal manifestations from inflammatory arthritis was central to this case. Although XLH is associated with pain, stiffness, enthesopathy and degenerative joint disease, erosive arthritis is not a typical feature. The radiographic pattern further supported an inflammatory aetiology: the erosions were marginal, located at the synovial reflection of the MCP and PIP joints, with periarticular osteopenia and ulnar deviation — a distribution characteristic of synovitis-driven bone destruction rather than the subperiosteal resorption, pseudofractures, or enthesopathic changes typical of metabolic bone disease. Calcium pyrophosphate deposition disease (CPPD) was considered given its reported association with metabolic disorders, including XLH[7], and its potential to mimic inflammatory arthritis[8]. However, the distribution of joint involvement, the presence of typical RA radiographic features including marginal erosions and MCP subluxation, the absence of chondrocalcinosis on wrist, knee and pelvic radiographs, and the sustained response to disease-modifying antirheumatic drugs (DMARDs) supported a diagnosis of seronegative RA. Erosive osteoarthritis was also considered unlikely given the predominant involvement of the MCP joints with sparing of the distal interphalangeal joints, along with the presence of periarticular osteopenia, marginal erosions and ulnar deviation, in contrast to erosive osteoarthritis, which shows an interphalangeal predominance, including the distal joints, with central erosions and osteophytes[9]. Synovial fluid analysis was not performed. Musculoskeletal ultrasound was also not performed; therefore, the presence of periarticular or intra-articular calcifications could not be assessed, and crystal deposition disease cannot be completely excluded. To our knowledge, reports describing the coexistence of genetically confirmed XLH and rheumatoid arthritis are lacking, with the available literature focusing mainly on XLH-associated enthesopathy, osteoarthritis and, less commonly, calcium pyrophosphate deposition disease. This case therefore highlights an important diagnostic pitfall, illustrating that new erosive inflammatory arthritis should not be automatically attributed to the underlying metabolic bone disease but should prompt consideration of a concomitant inflammatory rheumatic disease.

The case also underlines an important therapeutic pitfall. Multiple areas of increased uptake on bone scintigraphy were initially interpreted as insufficiency fractures, leading to bisphosphonate treatment before osteomalacia had been recognised. Ibandronate therapy was continued for approximately six years before the diagnosis of osteomalacia was established and was subsequently discontinued after the diagnosis of XLH was established. No clinically evident hypocalcaemia or other adverse events attributable to bisphosphonate therapy were documented. Nevertheless, in patients with unexplained hypophosphataemia, antiresorptive therapy should be avoided until osteomalacia and renal phosphate wasting have been excluded[1]; moreover, bisphosphonate-induced hypocalcaemia may exacerbate PTH elevation and, consequently, renal phosphate wasting, potentially compounding the underlying metabolic disorder. Lumbar spine DXA values are frequently confounded by mineralisation artefact, vertebral deformity, and enthesophyte formation in XLH — as illustrated by the spuriously elevated lumbar Z-score in this patient — and should be interpreted with caution[10]. The switch from calcifediol to calcitriol was prompted by the recognition that FGF23 inhibits renal 1α-hydroxylase and stimulates 24-hydroxylase, rendering native vitamin D supplementation insufficient to overcome the enzymatic block; active vitamin D is required to achieve adequate intestinal calcium absorption and mineralisation support[1]. Nephrocalcinosis is the most common renal complication of conventional XLH treatment and may progress to chronic kidney disease; regular monitoring of urinary and serum calcium is recommended, with dose adjustment of active vitamin D if hypercalciuria develops[1,10]. Treatment goals in adults with XLH include reducing pain, limiting the extent of osteomalacia, promoting fracture healing and improving physical function [1,10]. Burosumab, a monoclonal antibody targeting FGF23, is currently recommended for symptomatic adults with XLH who fulfil eligibility criteria despite conventional treatment with phosphate and active vitamin D. Clinical trials and real-world studies have demonstrated improvements in phosphate homeostasis, fracture healing, pain, stiffness and physical function[11,12]. The patient described is cur-

rently being evaluated for treatment, although access remains dependent on local reimbursement policies[10].

The diagnostic workup was delayed, reflecting the fragmented evaluation common in complex adult presentations. FGF23 assay details were incomplete, 1,25(OH)⊠D and aminoaciduria were unavailable. The significance of isolated urinary beta-2 microglobulin elevation remains uncertain, as isolated tubular injury is not a recognised feature of XLH and there is currently no consistent evidence that long-term phosphate supplementation alone causes this finding. Nevertheless, the biochemical pattern and genetic confirmation provide a robust diagnosis of XLH.

This case emphasises that XLH should be considered in adults with unexplained skeletal deformities and persistent hypophosphataemia, even in the absence of a family history. The central role of rheumatology-nephrology collaboration, from the investigation of renal phosphate wasting to long-term therapeutic monitoring, reflects the multidisciplinary approach recommended in current guidelines[1,10]. Careful reassessment of new musculoskeletal symptoms, particularly erosive arthritis, is essential to avoid misattribution to the underlying metabolic disorder and ensure timely management of coexisting conditions.

REFERENCES

1. Haffner D, Emma F, Seefried L, et al. Clinical practice recommendations for the diagnosis and management of X-linked hypophosphataemia. Nat Rev Nephrol. 2025;21(5):330-354. https://doi.org/10.1038/s41581-024-00926-x
2. Uday S, Mughal MZ, Cassinelli H, et al. Delayed diagnosis of X-linked hypophosphatemia in the absence of family history: a global unmet need. JBMR Plus. 2025;9(12). https://doi.org/10.1093/jbmrpl/ziaf158
3. National Center for Biotechnology Information. NM_000444.6 (PHEX):c.1645+1G>A AND Familial X-linked hypophosphatemic vitamin D refractory rickets. ClinVar. February 7, 2023. Accessed April 29, 2026. https://www.ncbi.nlm.nih.gov/clinvar/RCV000505469.4/
4. Steele A, Gonzalez R, Garbalosa JC, et al. Osteoarthritis, Osteophytes, and Enthesophytes Affect Biomechanical Function in Adults With X-linked Hypophosphatemia. J Clin Endocrinol Metab. 2020;105(4):e1798-e1814. https://doi.org/10.1210/clinem/dgaa064
5. Ito N. Adult Presentation of X-Linked Hypophosphatemia. Endocrines. 2022;3(3):375-390. https://doi.org/10.3390/endocrines3030030
6. Böckmann I, Haffner D. The Diagnosis and Therapy of XLH. Calcif Tissue Int. Springer. 2025;116(1). https://doi.org/10.1007/s00223-025-01374-w
7. Geetha Wickrematilake. Calcium Pyrophosphate Dihydrate Deposition Disease in Young Patients: Two Case Reports. Arch Rheumatol. 2017;32(1):080-083. https://doi.org/10.5606/ArchRheumatol.2017.6015
8. Abhishek A, Tedeschi SK, Pascart T, et al. The 2023 ACR/EULAR classification criteria for calcium pyrophosphate deposition disease. Ann Rheum Dis. 2023;82(10):1248-1257. https://doi.org/10.1136/ard-2023-224575
9. Ezzati F, Pezeshk P. Radiographic Findings of Inflammatory Arthritis and Mimics in the Hands. Diagnostics. 2022;12(9):2134. https://doi.org/10.3390/diagnostics12092134
10. Khan AA, Ali DS, Appelman-Dijkstra NM, et al. X-Linked Hypophosphatemia Management in Adults: An International Working Group Clinical Practice Guideline. J Clin Endocrinol Metab. 2025;110(8):2353-2370. https://doi.org/10.1210/clinem/dgaf170
11. Insogna KL, Briot K, Imel EA, et al. A Randomized, Double-Blind, Placebo-Controlled, Phase 3 Trial Evaluating the Efficacy of Burosumab, an Anti-FGF23 Antibody, in Adults With X-Linked Hypophosphatemia: Week 24 Primary Analysis. J Bone Miner Res. 2018;33(8):1383-1393. https://doi.org/10.1002/jbmr.3475
12. Bubbear J, Lachmann R, Murphy E, et al. Real-World Effectiveness of Burosumab in Adults with X-Linked Hypophosphataemia (XLH) in the UK. Calcif Tissue Int. 2025;116(1):122. https://doi.org/10.1007/s00223-025-01433-2