

CASE BASED REVIEWS

Pediatric Sjögren syndrome: case report on a rare entity

Santos MF¹, Linhares MI¹, Borges MI², Lopes MD³, Almeida V⁴, Salgado M¹, Nascimento J¹

ABSTRACT

Pediatric Sjögren's Syndrome (SS) is an auto-immune disorder of unknown prevalence with significant risk of comorbidity. In contrast to the classical dyad of xerostomia and xerophthalmia frequently seen in adults, in children and adolescents, recurrent parotiditis and sialadenitis are more often the presenting symptoms. We describe the case of a previously healthy 16-year-old girl with recurrent cervical lymphadenopathy and parotid swelling. Over the course of nine months, extensive investigation established chronic bilateral recurrent sialadenitis of unknown cause. The patient's clinic and complementary exams favor a primary SS diagnosis; however, she later meets classification criteria for Systemic Lupus Erythematosus. Although currently clinically stable under hydroxychloroquine with minor parotid swelling and eye redness, long term multidisciplinary follow-up will be needed to manage the patient's disease. This report aims to bring awareness to this diagnostic challenge and to the need for pediatric criteria for SS.

Keywords: Ultrasonography; Inflammation; Sjogren's syndrome; Paediatric/Juvenile rheumatology; Adolescent rheumatology.

INTRODUCTION

Sjögren's Syndrome (SS) is a systemic auto-immune disorder that leads to lymphocytic inflammatory injury of the exocrine glands¹⁻³. SS can be classified as primary (pSS), an idiopathic systemic syndrome, or secondary to rheumatoid arthritis, systemic lupus erythematosus, systemic sclerosis, among other auto-immune and auto-inflammatory entities, which comprise the majority of cases^{4,5}.

The chronic inflammatory injury primarily affects the lacrimal and salivary glands, resulting in dry mouth - xerostomia, dry eyes - xerophthalmia, and recurrent parotiditis⁶. Furthermore, pSS patients can present an extensive array of additional extraglandular systemic manifestations, like mild fever, leukopenia or arthralgias^{1,2,4,7}. Unfortunately, a higher risk of developing mucosa-associated lymphoid tissue (MALT) or B-cell lymphomas is also associated with pSS⁸.

Although pSS seems to affect 0.043% of the population², its true prevalence in children and adolescents is not known, despite the multiple single-case reports and case-series published so far^{9,10}.

This rare diagnosis is made even more challenging considering that this clinical presentation differs significantly from what is seen in adults^{1,2,5} (Table I). Sicca symptoms are less common in childhood⁹, especially at the onset of the disease, as a more advanced state of glandular damage is thought to be required for children to report these complaints. Recurrent parotitis is frequently the first and most predominant symptom^{5,6,9}. Differential diagnosis can hence be difficult as children more often present parotid swelling due to infectious, lymphoproliferative, and auto-immune causes other than SS^{5,11} (Table II).

CASE REPORT

An otherwise healthy 16-year-old girl, with no relevant family history, presents recurrent lymphadenopathy of unknown cause. The symptoms had been developing for the previous two months, with painless recurrent bilateral enlargement of submandibular, superficial, and posterior cervical nodes, that lasted a few weeks at a time. Although occasionally associated with superficial redness, neither fluctuation nor suppuration were ever noted. Malaise, fever, night sweats, weight loss, joint pain and breathlessness were denied, as well as any other systemic symptoms.

Preliminary investigation with the attending pediatrician had shown leukopenia (4200/uL), elevated sedimentation rate (47 mm/h), normal c-reactive protein and lactate dehydrogenase (0,1 mg/dL and 153 IU/L respectively). Thyroid function was also within normal limits (thyroid stimulating hormone 3 mIU/L, thyroxine

¹ Unidade de Reumatologia, Hospital Pediátrico - Centro Hospitalar e Universitário de Coimbra; ² Serviço de Estomatologia, Centro Hospitalar e Universitário de Coimbra; ³ Serviço de Estomatologia, Hospital Pediátrico - Centro Hospitalar e Universitário de Coimbra; ⁴ Serviço de Anatomia Patológica, Centro Hospitalar e Universitário de Coimbra

Correspondence to: Mariana Flório Santos
E-mail: marianaflioriosantos@hotmail.com

Submitted: 05/06/2022

Accepted: 06/08/2022

Table I. Adult vs Pediatric Manifestations of Sjögren's Syndrome - Major Features

Adult SS	<p>Dry mouth and eyes are the most common symptoms (80-90%). Xerostomia may be associated with dysphagia, cough, tooth loss, aphthae, candidiasis and angular cheilitis. Xerophthalmia can be complicated by keratoconjunctivitis sicca, blepharitis, keratitis, or corneal ulcer.</p> <p>Musculoskeletal symptoms like myalgias and joint inflammatory are very common (50-70%).</p> <p>Fatigue and non-restful sleep are reported in 50-80% of cases.</p> <p>Swelling of the parotid is reported in 30% of patients.</p>
Pediatric SS	<p>Recurrent parotitis - earliest and most predominant symptom (70-80%). Parents often report multiple episodes of parotid swelling where infectious causes were assumed.</p> <p>Xerophthalmia and xerostomia – less common as an early symptom - pronounced/early tooth decay can be an indirect sign of xerostomia and misperceived as lack of oral hygiene.</p> <p>Arthralgias and fever can occur in 10% of children.</p> <p>Other presenting symptoms reported in pediatric cases: renal tubular acidosis, central and peripheral nervous system involvement, erythema annulare, thyroiditis, vulvovaginitis, hepatitis, and Raynaud phenomenon.</p>

SS – Sjögren's Syndrome.

Table II. Differential Diagnosis of Parotid Swelling in Children

Infectious Causes	<p>Viral parotitis (<i>paramyxovirus</i>, <i>coxsackie virus</i>, <i>cytomegalovirus</i>, <i>parainfluenza</i>, Epstein-Barr virus).</p> <p>Bacterial parotitis (<i>Staphylococcus aureus</i>, <i>Streptococcus viridans</i>, <i>Haemophilus influenzae</i>)</p> <p>Cat scratch disease, tuberculosis.</p>
Autoimmune and Inflammatory Causes	Sjögren's syndrome, rheumatoid arthritis, systemic lupus erythematosus, IgG4-related disease, sarcoidosis, amyloidosis.
Lymphoproliferative Causes and Tumors	Hemangioma, Pleomorphic adenoma, dermoid cyst. Lymphomas (Burkitt, Non-Hodgkin, Hodgkin).
Miscellaneous	Reactive adenopathy, juvenile recurrent parotitis, sialolithiasis, parotid trauma/surgery, drug exposure (iodides), radiation therapy.

1,29 ng/dl) with elevated anti-thyroglobulin (626 IU/mL) and anti-thyroid peroxidase (410 IU/mL) antibodies. Cervical ultrasonography showed a normal thyroid gland, generalized bilateral enlargement of the lymph nodes of the lower facial and cervical regions, globous heterogeneous parotid and submandibular glands, as well as hypoechoic intraglandular micronodules. Both the left parotid and an intraparotidic node were aspirated. Pathology reported lymphocytic infiltration, suggestive of reactive lymphadenitis. Two courses of antibiotics, cefaclor and amoxicillin/clavulanic acid, were completed without clinical improvement.

Throughout the following four months, our patient experienced recurrent lymphadenopathy and parotid enlargement, which led to the referral for a pediatric infectious disease consult in our hospital.

In this consult, additional investigation was conducted. No serologic evidence of Epstein-Barr Virus, Cytomegalovirus, Human Immunodeficiency Virus types 1 and 2 or *Bartonella henselae* infections were found. QuantiFERON®-TB was also negative. Urinalysis, pe-

ripheral blood smear, thyroid, hepatic, and renal functions were normal. Lactate dehydrogenase, uric acid and alkaline phosphatase were within normal ranges (141 IU/L, 4,2mg/dL and 102 IU/L respectively). Sustained leukopenia of 4200-4300/uL (4500-11000/uL), lymphopenia of 1380-1460/uL (1500-4800/uL), elevated erythrocyte sedimentation rate of 33-44 mm/h, and c-reactive protein 0,1-5 mg/dL were also noted. Serum protein electrophoresis showed polyclonal hypergammaglobulinemia (IgG of 28,51 g/L, subtype IgG1 of 26,5 g/L with normal IgG4).

Thoracic X-ray and computed tomography come back normal. Lumbar, abdominal, renal, and pelvic ultrasounds also presented no significant findings. The patient was submitted to a second parotid gland ultrasound which excluded sialolithiasis and showed bilateral heterogeneous micronodular enlargement of parotid and submandibular glands (Fig. 1), similarly to what had been previously reported. Fine-needle aspiration was repeated for *Mycobacterium tuberculosis* cultures, which were negative.

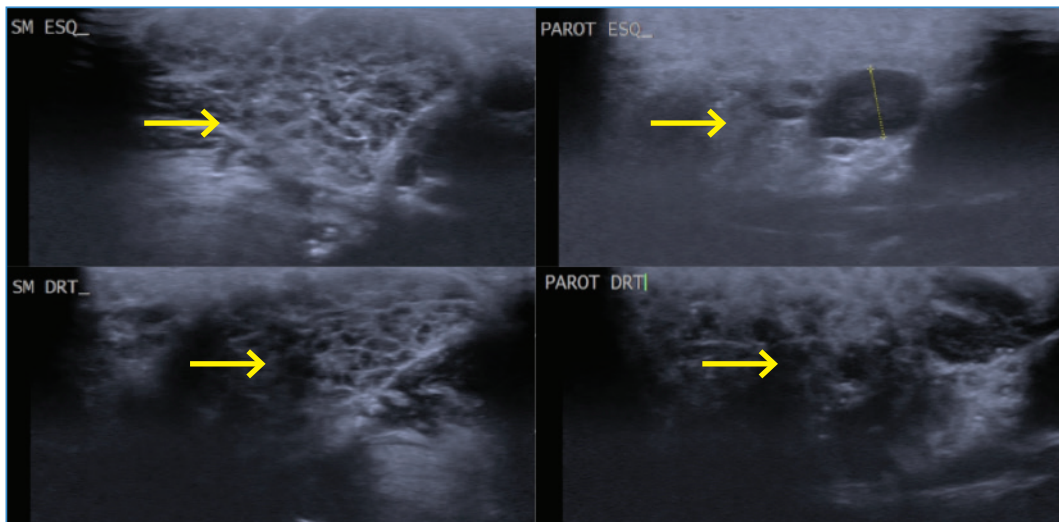


Figure 1. Left (ESQ) and right (DIR) parotid (PAROT) and submandibular (SM) gland ultrasound frames showing heterogenous micronodular enlargement.

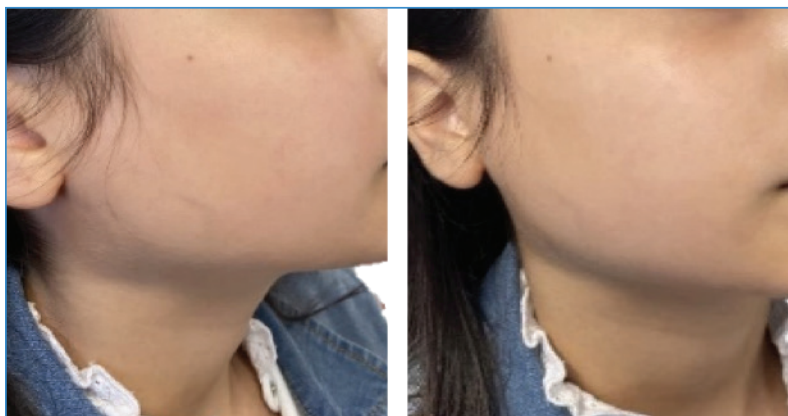

Figure 2. Right Parotid Gland Inflammation

At this point, a diagnosis of chronic bilateral sialadenitis involving the parotid and submandibular glands was established. No evidence of an obstructive, traumatic, lymphoproliferative/neoplastic, or infectious cause had been found so far. Suspicion of an autoimmune/autoinflammatory etiology led to a rheumatology consult.

The patient was brought to our pediatric rheumatology consult nine months after the first symptoms arose, and had developed recurrent bilateral conjunctival hyperaemia, fatigue, and sporadic headaches. Xerophthalmia, xerostomia, vaginal dryness, respiratory symptoms and fever were denied. On examination, the girl presented right parotid tumefaction (Fig. 2), multiple palpable cervical and submandibular ganglia, one of which with >2 cm of diameter, and redness on her left eye. No evidence of oral cavities, aphthae, alopecia, serositis, arthritis, cutaneous, gynecological, or neurological involvement was found, with an otherwise normal

physical exam. Her vital parameters, including blood pressure, were normal for age and gender.

Despite the lack of sicca symptoms and normal ophthalmology observation, Schirmer test showed a slight decrease in basal tear secretion on her left eye (R:13mm/L:8mm, normal range values 10-15mm, xerophthalmia <5mm). Labial salivary gland biopsy (Fig. 3) showed lymphocytic infiltration with an elevated focus score (number of mononuclear cell infiltrates containing at least 50 inflammatory cells in a 4 mm² glandular section) of >1 foci/4mm². These results were consistent with lacrimal and salivary glands inflammatory injury.

The first immunological work-up revealed positive rheumatoid factor (36 IU/ml), positive direct antiglobulin test, and positive anti-nuclear (>1:1280), anti-SSA and anti-SSB antibodies. Serum amylase was 149 U/L, C3 0,97 g/L, C4 0,14 g/L, erythrocyte sedimentation rate 42 mm/h and c-reactive protein 0,04 mg/dL. Immunoglobulins IgA and IgM were normal, with elevat-

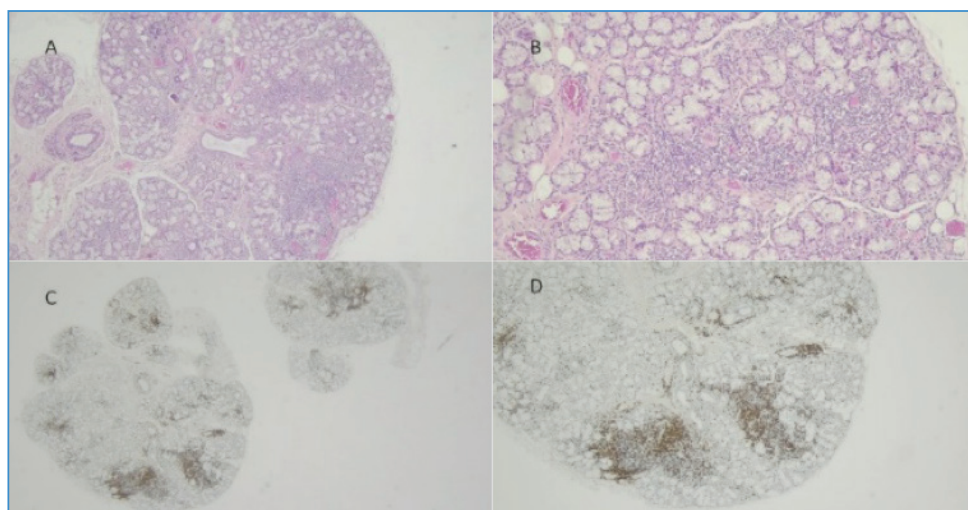


Figure 3. Labial salivary gland biopsy section showing peri-epithelial mononuclear cell infiltrates. A and B - Hematoxylin and eosin stain 100x and 200x. C and D - Immunohistochemistry staining for CD20 showing large foci of B cell infiltrate 20x and 100x.

ed IgG (25,91 g/L), IgG1 (22,3 g/L), and normal IgG4 (0,24 g/L). Angiotensin-converting enzyme was negative (43U/L). A pSS diagnosis appeared to be the most probable diagnosis considering our patients' findings as no clinical evidence of other auto-immune diseases was present.

Fifteen months after presentation, she complained of joint pain, specifically hands, wrists, knees and hips, without morning stiffness or evidence of arthritis on observation. A negative response to ibuprofen (400mg 1-3 times daily) led to the decision to start hydroxychloroquine 400mg once daily, with excellent results. Adding to the sustained leucopenia, elevated sedimentation rate (24-44mm/h) and hypergammaglobulinemia, anti-double stranded DNA (anti-dsDNA) antibodies (14 IU/mL) were identified once, with subsequent normalization.

Artificial tears, and non-pharmacological stimulation of salivary glands were recommended in addition to the hydroxychloroquine for arthralgia. Under multidisciplinary clinical surveillance, involving rheumatology, ophthalmology, stomatology, gynecology and psychology consults, she has remained clinically stable with painless recurrent cervical lymphadenopathy, minor parotid swelling, sporadic eye redness and no gynecologic involvement. No other therapies have been necessary to manage our patient's symptoms so far. Future follow-up has already been guaranteed with an age transition consult with both adult and pediatric rheumatologists.

DISCUSSION

The first pediatric classification criteria for SS were proposed in 1999 by Bartunkova, *et al*¹⁰, which included clinical, immunological and laboratory findings, and

exclusion of other autoimmune diseases. Throughout the years, authors concluded this classification lacked sensitivity^{12,13} which eventually led to the application of the American College of Rheumatology/European League Against Rheumatism (ACR/EULAR) classification criteria for pSS¹⁴. Using adult criteria turned out not to be consensual. Some experts determined the majority of children diagnosed with SS did not meet adult criteria¹⁵, while others found the application of EULAR's Sjögren's syndrome disease activity index (ESSDAI)¹⁶ to be useful for assessing disease activity in childhood¹⁷. Nonetheless, the need for standardized, widely accepted diagnostic criteria for pediatric patients is unanimous. There is no evidence of significant differences between adult and pediatric immunological profiles⁵, but broadening clinical criteria and including salivary gland ultrasound in the diagnostic algorithm seem important steps^{13,18}.

When we first studied our patient, we were able to positively support a diagnosis applying Bartunkova's criteria (Table III). Although not technically fulfilling criteria III. 6 and 7, our patient still showed an abnormal Schirmer test unilaterally and undeniable clinical and ultrasonographic evidence of salivary gland affection. In addition to this, we applied ACR/EULAR's classification criteria for primary Sjögren's syndrome¹⁴ (Table IV). We considered our patient met inclusion criteria through suspicion of SS and by scoring three domains in EULAR's Sjögren's syndrome disease activity index (ESSDAI)¹⁶ questionnaire. Scored domains were the Lymphadenopathy and Lymphoma Domain (lymphadenopathy ≥ 2 cm in any nodal region, with exclusion of infection), Glandular Domain (small glandular swelling with enlarged parotid (≤ 3 cm), or limited submandibular (≤ 2 cm), with exclusion of stone

Table III. Bartunkova et al. Primary Sjögren's syndrome in children and adolescents: proposal for diagnostic criteria¹⁰

I. Clinical symptoms	<ol style="list-style-type: none"> 1. Oral: recurrent parotitis or enlargement of parotid gland. Ocular: recurrent conjunctivitis without obvious allergic or infectious etiology, keratoconjunctivitis sicca Other mucosal: recurrent vaginitis Systemic: a) fever of unknown origin; b) non-inflammatory arthralgias, c) hypokalemic paralysis, d) abdominal pain
II. Immunologic abnormalities	Presence of at least one of the following antibodies: anti-SSA, anti-SSB, high title of antinuclear antibody, rheumatoid factor.
III. Other laboratory abnormalities or additional investigations	<ol style="list-style-type: none"> 1. Biochemical: elevated serum amylase 2. Hematological: leucopenia, high erythrocyte sedimentation rate 3. Immunologic: polyclonal hyperimmunoglobulinemia Nephrological: renal tubular acidosis 5. Histological proof of lymphocytic infiltration of salivary glands or other organs. Objective documentation of ocular dryness (Bengal red staining or Schirmer test) Objective documentation of parotid gland affection (Scintigraphy)
IV. Exclusion of all other autoimmune diseases.	

Diagnosis – presence of ≥ 4 criteria. All criteria positive in our patient are in bold.

or infection), and Biological Domain (presence of hypergammaglobulinemia or high IgG level >20 g/L). No exclusion criteria were met at the time. Labial salivary gland with focal lymphocytic sialadenitis, focus score ≥ 1 and positive Anti-SSA antibodies meant our patient met criteria for pSS with a score of 6.

As far as differential diagnosis is concerned, it was important for our team to closely monitor the patient clinically and immunologically. Although classification criteria are helpful in rare diseases and provide guidance, they should not be confused with diagnostic criteria, which should above all be based on clinical aspects and complemented by other exams. Lack of clinical suspicion, the patient's age, normal angiotensin conversion enzyme and absence of noncaseating granulomas, monoclonal plasma cell disorders and amyloid substance in histology, steered us away from sarcoidosis and amyloidosis. IgG4-related disease (IgG4-RD) presents similarly to SS with major salivary gland involvement, which led us to readily monitor for other systemic symptoms and IgG4 levels. However, in our case, positive anti-SS-A and SS-B antibodies met exclusion criteria according to the 2019 ACR/EULAR's Classification Criteria for IgG4-related disease¹⁹.

A "clinically silent" systemic lupus erythematosus (SLE) as a possible primary cause of SS had always been an undeniable possibility in this case. As this would significantly impact our patient's prognosis and follow up, close monitoring was necessary. For the first year of disease, application of 2019 ACR/EULAR's classification criteria for SLE²⁰, with positive antinuclear anti-

bodies $>1:80$, leukopenia $<4000/uL$, and low C3, made a SLE diagnosis seem very unlikely. At this point, pSS was the most probable diagnosis. It was only recently, with a single positive result for anti-dsDNA (14 IU/mL by fluoroenzyme immunoassay), which has normalized since, that SLE criteria were technically met. When looking at SS, Basiaga *et al*¹⁵ showed that 12 out of 300 cases of pediatric SS with a history of parotitis fulfilled SLE criteria. Although it is not known how prevalent positive anti-dsDNA antibodies are in pSS, cases have been reported in adults⁹.

Our treatment options followed EULAR's recommendations for the management of Sjögren's syndrome with topical and systemic therapies²¹, which presents multiple therapeutic algorithms according to disease severity. The course of treatment is individualized and dependent on the patient's symptoms. The approach to dryness is symptomatic with topical treatments according to site as systemic therapies are considered for active systemic disease. Oral dryness can be managed with non-pharmacological stimulation (sugar-free acidic candies or chewing gum), pilocarpine, saliva substitutes, N-acetylcysteine, or even electrostimulation. Ocular dryness follows the same principles (artificial tears, followed by topical steroids and eventually muscarinic agonists). Acute glandular involvement is managed symptomatically with non-steroidal anti-inflammatory drugs (NSAID), but lack of response may portray the need for glucocorticoids, rituximab or belimumab. Our patient presented arthralgias which did not respond to the first line of treatment (NSAID), and HCQ was

Table IV. American College of Rheumatology/ European League Against Rheumatism Classification Criteria for Primary Sjögren's Syndrome (abridged)¹⁴

The classification applies to any individual who meets the inclusion criteria ¹ , does not have any condition listed as exclusion criteria ² , and who has a score ≥ 4 when summing the weights from the following items:	
Item	Weight/Score
Labial salivary gland with focal lymphocytic sialadenitis and focus score $\geq 1$³	3
Anti-SSA (Ro) +	3
Ocular staining score ≥ 5 (or van Bijsterveld score ≥ 4) on at least one eye ⁴	1
Schirmer ≤ 5 mm/5min on at least one eye	1
Unstimulated whole saliva flow rate ≤ 0.1 ml/min ⁵	1

¹Inclusion criteria: applicable to any patient with at least one symptom of ocular or oral dryness (defined as a positive response to at least one of the following questions: 1) Have you had daily, persistent, troublesome dry eyes for more than 3 months? 2) Do you have a recurrent sensation of sand or gravel in the eyes? 3) Do you use tear substitutes more than 3 times a day? 4) Have you had a daily feeling of dry mouth for more than 3 months? 5) Do you frequently drink liquids to aid in swallowing dry food?); or **suspicion of SS from ESSDAI questionnaire (at least one domain with positive item)**

²Exclusion criteria: Prior diagnosis of any of the following conditions would exclude diagnosis of SS and participation in SS studies or therapeutic trials because of overlapping clinical features or interference with criteria tests: history of head and neck radiation treatment, active hepatitis c infection, acquired immunodeficiency syndrome, sarcoidosis, amyloidosis, graft versus host disease, IgG4-related disease.

Patients who are normally taking anticholinergic drugs should be evaluated for objective signs of salivary hypofunction and ocular dryness after a sufficient interval off these medications for these components to be a valid measure of oral and ocular dryness. ³The histopathologic examination should be performed by a pathologist with expertise in the diagnosis of focal lymphocytic sialadenitis and focus score count (based on number of foci per 4 mm²) following a protocol described in Daniels et al 2011. ⁴Ocular staining score described in Whitcher et al 2010, van Bijsterveld score described in van Bijsterveld 1969. ⁵Unstimulated whole saliva described in Navazesh & Kumar, 2008

SS - Sjögren's Syndrome; All criteria positive in our patient are in bold.

started. If arthritis had been present, glucocorticoids, followed by oral immunosuppressive agents like methotrexate would have been therapeutic options. In SS, there is no evidence that treatment will at this point modify disease, and therapeutic targets seem to be far from being set²¹.

Even if the presence of pediatric SS is undisputable in this case, only time will show if our patient will in fact clinically develop SLE. Our goal is to continue to help manage her symptoms and monitor for systemic complications. Early diagnosis and multidisciplinary approach increase chances of minimal comorbidities,

assuring a higher standard of care on the long term.

This case illustrates the challenging path pediatric SS patients face until diagnosis. The lack of standardized, widely accepted diagnostic criteria for pediatric patients massively contributes to its underdiagnosis. There is a need for international collaborative studies to better define and understand the natural history of SS in children and adolescents and help set plans for the future of patients like ours. Although there is extensive evidence on the differences between pediatric and adult symptoms, this knowledge is yet to be shared between most general clinicians and pediatricians⁶. It is our hope that our report contributes to changing this paradigm.

REFERENCES

- Vivino F, Bunya VY, Massaro-Giordano G, et al. Sjogren's syndrome: An update on disease pathogenesis, clinical manifestations and treatment. *Clin Immunol.* 2019;203(April):81-121. doi:10.1016/j.clim.2019.04.009
- Parisis D, Chivasso C, Perret J, Soyfoo MS, Delporte C. Current State of Knowledge on Primary Sjögren's Syndrome, an Autoimmune Exocrinopathy. *J Clin Med.* 2020;9(7):2299. doi:10.3390/jcm9072299
- Aburiziza AJ, Basiaga ML, Stern SM, et al. Acta Médica Portuguesa's Publishing Guidelines. *Rheumatology.* 2020;18(2):1-13. doi:10.1093/rheumatology/keaa757
- Marino A, Romano M, Giani T, et al. Childhood Sjogren's syndrome: An Italian case series and a literature review-based cohort. *Semin Arthritis Rheum.* 2020;000. doi:10.1016/j.semarthrit.2020.11.004
- Cimaz R, Casadei A, Rose C, et al. Primary Sjögren syndrome in the paediatric age: A multicentre survey. *Eur J Pediatr.* 2003;162(10):661-665. doi:10.1007/s00431-003-1277-9
- Tomita M, Kobayashi I, Itoh Y, et al. Clinical practice guidance for Sjögren's syndrome in pediatric patients (2018) summarized and updated. *Mod Rheumatol.* 2021;31(2):283-293. doi:10.1080/14397595.2020.1816319
- Jain G, Kalra S, Vasnik G, Bhandari S. Primary Sjogren's syndrome manifesting with distal renal tubular acidosis and severe metabolic bone disease. *BMJ Case Rep.* 2020;13(6):10-13. doi:10.1136/bcr-2020-234929
- Alunno A, Leone MC, Giacomelli R, Gerli R, Carubbi F. Lymphoma and lymphomagenesis in primary Sjögren's syndrome. *Front Med.* 2018;5(APR):1-7. doi:10.3389/fmed.2018.00102
- Virdee S, Greenan-Barrett J, Ciurtin C. A systematic review of primary Sjögren's syndrome in male and paediatric populations. *Clin Rheumatol.* 2017;36(10):2225-2236. doi:10.1007/s10067-017-3745-z
- Bartůňková J, Šedivá A, Vencovský J, Tesař V. Primary Sjogren's syndrome in children and adolescents: Proposal for diagnostic criteria. *Clin Exp Rheumatol.* 1999;17(3):381-386.
- Abdel Razeq AAK, Mukherji S. Imaging of sialadenitis. *Neuroradiol J.* 2017;30(3):205-215. doi:10.1177/1971400916682752
- Houghton K, Malleson P, Cabral D, Petty R, Tucker L. Primary Sjögren's syndrome in children and adolescents: Are proposed diagnostic criteria applicable? *J Rheumatol.* 2005;32(11):2225-2232.
- Aburiziza AJ. Primary Juvenile Sjögren's syndrome in a 3-year-old pediatric female patient: Diagnostic role of salivary gland ultrasonography: Case report. *Open Access Rheumatol Res Rev.*

- 2020;12:73-78. doi:10.2147/OARRR.S248977
14. Shiboski CH et al. 2016 Classification Criteria for primary Sjögren's Syndrome: A Consensus and Data-Driven Methodology Involving Three International Patient Cohorts. *Accept Publ Ann Rheum Dis Arthritis Rheum*. 2016;69(1):35-45. doi:10.1002/art.39859.2016
 15. Basiaga ML, Stern SM, Mehta JJ, et al. Childhood Sjögren syndrome: features of an international cohort and application of the 2016 ACR/EULAR classification criteria. *Rheumatology*. 2020;1-12. doi:10.1093/rheumatology/keaa757
 16. Seror R, Bowman SJ, Brito-Zeron P, et al. EULAR Sjögren's syndrome disease activity index (ESSDAI): A user guide. *RMD Open*. 2015;1(1):1-9. doi:10.1136/rmdopen-2014-000022
 17. Iwata N, Tomiita M, Kobayashi I, et al. Utility of the EULAR Sjögren syndrome disease activity index in Japanese children: A retrospective multicenter cohort study. *Pediatr Rheumatol*. 2020;18(1):1-7. doi:10.1186/s12969-020-00458-1
 18. Krumrey-Langkammerer M, Haas JP. Salivary gland ultrasound in the diagnostic workup of juvenile Sjögren's syndrome and mixed connective tissue disease. *Pediatr Rheumatol*. 2020;18(1):1-8. doi:10.1186/s12969-020-00437-6
 19. Wallace ZS, Naden RP, Chari S, et al. The 2019 American College of Rheumatology/European League Against Rheumatism Classification Criteria for IgG4-Related Disease. *Arthritis Rheumatol*. 2020;72(1):7-19. doi:10.1002/art.41120
 20. Aringer M, Costenbader K, Daikh D, et al. 2019 European League Against Rheumatism/American College of Rheumatology classification criteria for systemic lupus erythematosus. *Ann Rheum Dis*. 2019;78(9):1151-1159. doi:10.1136/annrheumdis-2018-214819
 21. Ramos-Casals M, Brito-Zerón P, Bombardieri S, et al. EULAR recommendations for the management of Sjögren's syndrome with topical and systemic therapies. *Ann Rheum Dis*. 2020;79(1):3-18. doi:10.1136/annrheumdis-2019-216114