

CASE BASED REVIEWS

Pulmonary manifestations of VEXAS syndrome with acute interstitial pneumonia and diffuse alveolar hemorrhage: a case report and literature review

Puseljic M¹, Schmid J¹, Igrec J¹, Hatzl S², Scholz L², Wölfler A³, Fuchsjäger M¹, Talakic E¹

ABSTRACT

Vacuoles, E1 enzyme, X-linked, autoinflammatory, somatic (VEXAS) syndrome is an emerging adult-onset systemic autoinflammatory disorder affecting multiple organ systems. While lung involvement is common in this syndrome, literature regarding specific patterns is sparse. In this report, we present a case description of a patient with VEXAS syndrome who presented at the emergency department on two separate occasions with acute interstitial pneumonia (AIP) and diffuse alveolar hemorrhage (DAH). A literature review with a comparison of our observed findings to the general findings of VEXAS syndrome, AIP, and DAH is provided. This report underscores the rarity of specific pulmonary manifestations associated with VEXAS syndrome, contributing valuable insight to the limited literature available on this topic.

Keywords: Autoinflammatory disease; Interstitial lung disease; Diffuse alveolar hemorrhage; Acute interstitial pneumonia; Computed tomography.

INTRODUCTION

Vacuoles, E1 enzyme, X-linked, autoinflammatory, somatic (VEXAS) syndrome is a recently described adult-onset systemic autoinflammatory disorder caused by an acquired monogenic somatic mutation in the Ubiquitin Like Modifier Activating Enzyme 1 (UBA1) gene, which leads to reduced ubiquitination of misfolded cytoplasmic proteins and consequently to activation of autoinflammatory pathways¹. Besides commonly observed constitutional symptoms like noninfectious fever, fatigue, weight loss, and myalgia accompanied by elevated acute-phase reactants and progressive cytopenia, a wide spectrum of autoinflammatory presentations affecting multiple organ systems have been reported². Usually, an interdisciplinary approach is necessary for the diagnosis and therapy of such patients. While lung involvement is common, the literature regarding specific patterns is limited³.

This case report outlines two pulmonary manifestations of this syndrome: acute interstitial pneumonia

(AIP) and diffuse alveolar hemorrhage (DAH). The discussion includes a literature review and a comparison of our observed findings to the general characteristics of VEXAS syndrome, AIP, and DAH.

CASE DESCRIPTION

A 76-year-old male patient with VEXAS syndrome presented at the emergency department with newly developed dyspnea. The patient's initial manifestations of VEXAS syndrome had started 3 years before with fever of unknown origin, scrotal edema, unilateral parotitis, erythematous skin indurations, idiopathic orbital inflammatory disease, and macrocytic anemia (hemoglobin 9.8 g/dl, mean corpuscular volume 104 fl). A skin biopsy revealed leukocytoclastic vasculitis (LCV). Standard laboratory screening for connective tissue diseases, including antineutrophilic cytoplasmic antibodies, anticardiolipin antibodies and anti-beta-2-glycoprotein-I antibodies, was negative on several occasions. Due to inadequate response to antibiotic and corticosteroid therapy, a bone marrow biopsy was performed that showed hypercellularity, mild dysplasia, and a clonal cytopenia with a Ten-Eleven-Translocation oncogene family member 2 (TET2) mutation of unknown significance. At that time, the diagnosis of LCV associated with myelodysplastic syndrome had been made. Past medical history also involved 3 episodes of pneumonia (Figure 1), which had been clas-

¹ Department of Radiology, Division of General Radiology, Medical University of Graz; ² Department of Internal Medicine, Intensive Care Unit, Medical University of Graz; ³ Department of Internal Medicine, Division of Hematology, Medical University of Graz.

Submitted: 11/01/2024

Accepted: 24/02/2024

Correspondence to Jasminka Igrec
E-mail: jasminka.igrec@medunigraz.at

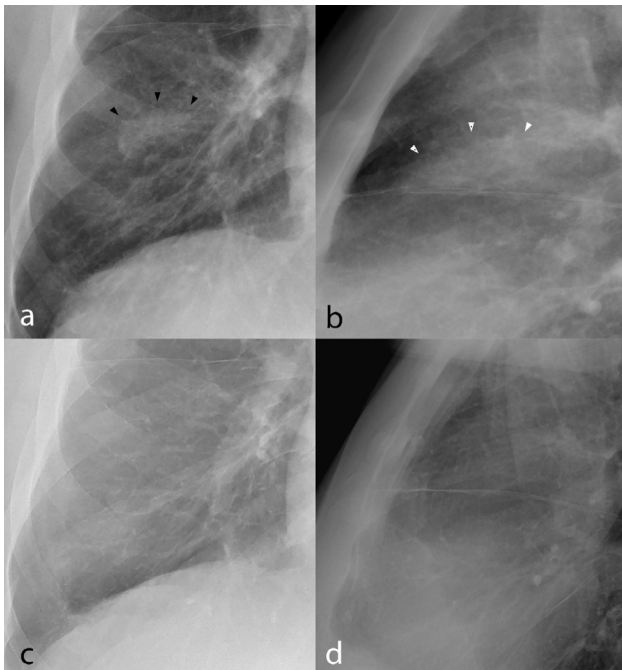


Figure 1. The patient's past medical history reveals three episodes of pneumonia before the described emergency visits. In one episode, a middle lobe infiltrate was revealed on a p.a. (a) and lateral plain chest radiograph (b) (between arrowheads). For comparison, a plain chest radiograph in p.a. (c) and lateral projections (d) taken before the diagnosis of VEXAS syndrome. p.a. = posteroanterior, VEXAS = Vacuoles, E1 enzyme, X-linked, autoinflammatory, somatic.

sified as infectious and successfully treated with antibiotic therapy. The diagnosis of VEXAS syndrome was eventually established after histologic reevaluation of the bone marrow biopsy showing cytoplasmic vacuoles in myeloid and erythroid precursor cells as well as the detection of a pathognomonic UBA1 p.M41T mutation.

The present emergency visit was characterized by severe dyspnea with a reduced oxygen saturation (SatO₂) of 74% and mild tachycardia (124/min). The arterial blood gas analysis showed a respiratory failure type 1 with reduced partial pressure of oxygen (PaO₂, 67.5 mmHg) and carbon dioxide (PaCO₂, 29.8 mmHg). Besides a leukocytosis (30.2 x 10⁹/L), elevated C-reactive protein (CRP, 92 mg/L), slightly elevated procalcitonin (0.60 ng/mL), and reduced hemoglobin (Hb, 8.8 g/dl), an elevated D-Dimer level was found (2.1 mg/L). Thus, a CT scan for the exclusion of pulmonary embolism (PE) was performed (Figure 2). The CT showed distinctive bilateral symmetrically distributed ground glass opacities (GGO), predominantly in the mid and lower lobes with few areas of patchy consolidations in the peripheral and lower lung segments. Prominent interlobular septal thickening was bilaterally present with delicate intralobular septal thickening. Sharply

demarcated areas of spared individual lobules with an overall geographic appearance were also noted. Signs of lung fibrosis were not evident. Mediastinal and right hilar lymphadenopathy was present, with a short axis length of to 1,4 cm. No PE, pleural effusions, aortic wall thickening, aortic dilatation, or abnormalities in the tracheobronchial structures were detected. Subsequently, after ICU admission a plain chest radiograph was taken (Figure 3, a-b). The patient showed good improvement under therapy with dexamethasone (20mg QD with subsequent tapering), an empiric antibiotic (piperacillin/tazobactam 4.5g QID), and the Janus kinase (JAK) inhibitor ruxolitinib (5mg, BID). Blood cultures, sputum, and serology were negative for infectious agents. Therefore, a diagnosis of an AIP was made. Due to the good response, a lung biopsy or bronchoscopy was not initiated. The patient was successfully discharged after 5 days.

One month later the patient presented again in our emergency department due to profound hemoptysis with respiratory failure type 1 (PaO₂ 48.3, PaCO₂ 34.5 mmHg), leucopenia (3.3 x 10⁹/L), worsening anemia (Hb 7.3 g/dl), elevated procalcitonin (0.65 ng/mL) and a CRP level of 316 mg/L. Another CT scan was performed (Figure 4) and bilateral centrilobular consolidations with a perilesional GGO halo around the centrilobular components in a random and asymmetrical distribution were found. Changes were more dominant in the mid and lower lung parts, with sparing of the apical segments and patchy confluent areas of consolidations in the basal lung segments. Interlobular septal thickening with a small pleural effusion on the right side was also noted. The lymphadenopathy remained unchanged. A PE was not confirmed. A plain chest radiograph was subsequently performed (Figure 3, c-d). In summary, these findings were suggestive of DAH. A lung biopsy or bronchoscopy was not performed. The previous corticosteroid therapy was adopted and an empiric antibiotic therapy (piperacillin/tazobactam 4.5g QID and azithromycin 500mg QD) was re-initiated. The patient showed prompt clinical improvement and was discharged after 4 days at his wish with regularly scheduled outpatient follow-ups. Currently, the patient is doing well on ruxolitinib (5 mg BID) and low-dose prednisone (2.5 mg QID) without any respiratory restraints.

DISCUSSION

VEXAS syndrome most commonly presents in males above the age of 50 as a progressive autoinflammatory condition affecting several organs with a wide spectrum of clinical findings⁴. Skin involvement occurs in up to 90% of patients with a variety of manifestations

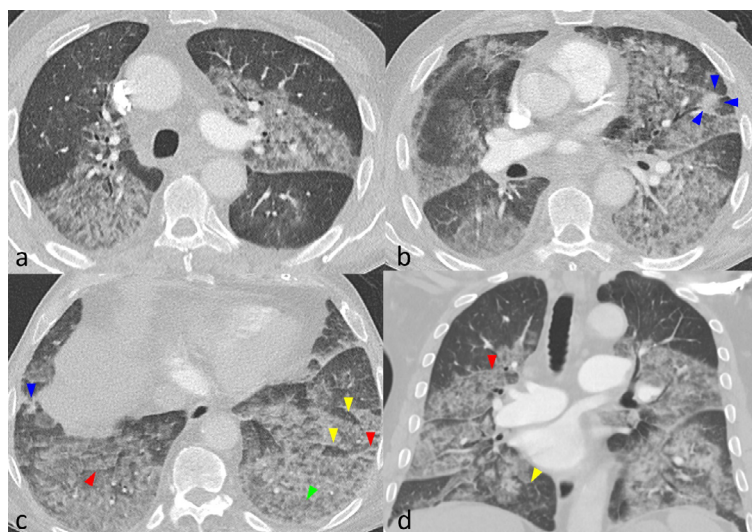


Figure 2. Contrast-enhanced chest CT in axial and coronal lung window reconstructions with 1.25 mm slice thickness. (a) Bilateral GGO affecting the central and subpleural lung segments. (b) Patchy consolidations in the lingual segment (blue arrowheads). (c) A geographic appearance is noted, with sparing of individual lung lobules (yellow arrowheads). Interlobular septal thickening is present bilateral (red arrowheads) with also intralobular septal thickening (green arrowheads). Patchy consolidations are also noted in the right anterobasal lower lobe segment (blue arrowhead). (d) Coronal reconstruction shows symmetrically distributed GGO with marked thickening of the interlobular septa (red arrowheads) and sparing of individual lobules (yellow arrowheads). CT = computed tomography, GGO = Ground glass opacities.

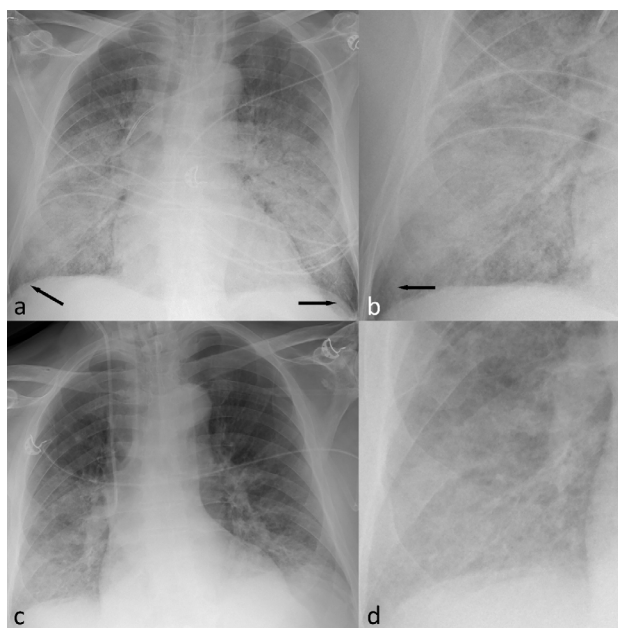


Figure 3. Two Supine plain chest radiographs in a.p. projection, taken during the first ICU admission when the patient presented with AIP (a-b) and during the second admission when the patient presented with DAH (c-d). (a) Symmetrically distributed GGO and airspace consolidations in the mid and lower lung segments with sparing of the costophrenic angles (arrows). (b) An enlarged view of the same radiograph (a), showing airspace consolidations and GGO. Note the sparing of the costophrenic angle (arrow). (c) Bilateral airspace consolidations and confluent GGO on the lower lung parts without sparing of the costophrenic angles. (d) An enlarged view of the same radiograph (c). a.p. = anteroposterior, AIP = acute interstitial pneumonia, DAH = diffuse alveolar hemorrhage, ICU = intensive care unit, GGO = ground glass opacities.

including LCV, Sweet syndrome–like skin lesions, or septal panniculitis^{4, 5}. Lung involvement is the second most common manifestation, occurring in 50–72% of patients^{1,3}. Unspecific hematologic abnormalities like anemia, thrombocytopenia, or leucopenia are present in almost all cases, while other abnormalities like myelodysplasia (50%), monoclonal gammopathy of undetermined significance (13%) or multiple myeloma (case

report) are less frequently observed⁶. Chondritis and tendinitis are two additional manifestations that are strongly associated with VEXAS syndrome⁴.

Lung involvement is often severe leading to significant morbidity and mortality. GGO (87%) and consolidations (49%) are the most commonly reported parenchymal changes on CT scans^{3, 7}, which are often characterized as non-specific interstitial pneumonia,

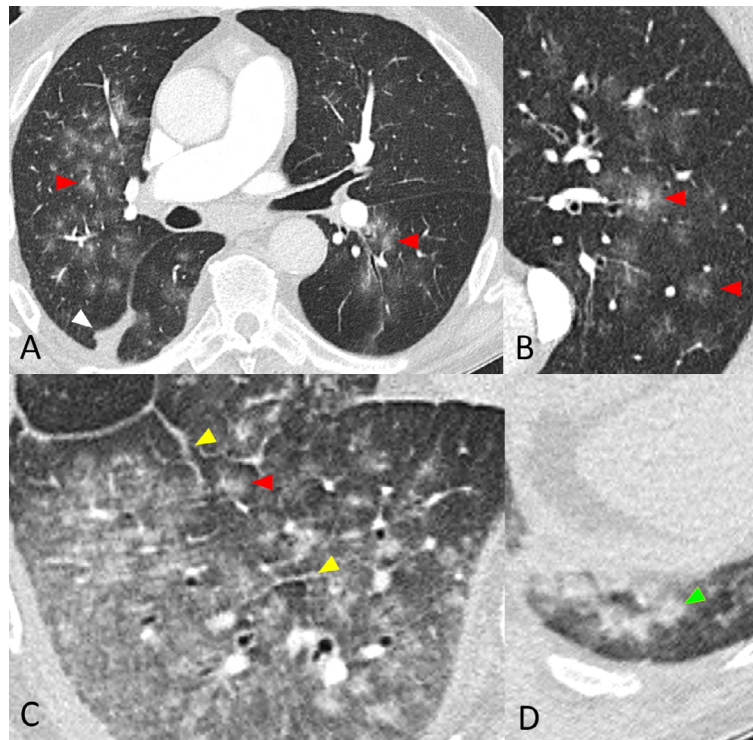


Figure 4. Contrast-enhanced chest CT in axial lung window reconstructions with 1.25 mm slice thickness. (a) Bilateral asymmetric centrilobular consolidations and GGO in a random distribution (red arrowheads) with a small pleural effusion (white arrowhead). (b) Centrilobular consolidation with a perilesional halo (red arrowheads). (c) Interlobular septal thickening (yellow arrowhead) with centrilobular consolidations (red arrowhead) in the right lower lobe. (d) Patchy confluent consolidations in the dorsobasal left lower lobe (green arrowhead). CT = computed tomography, GGO = ground glass opacities.

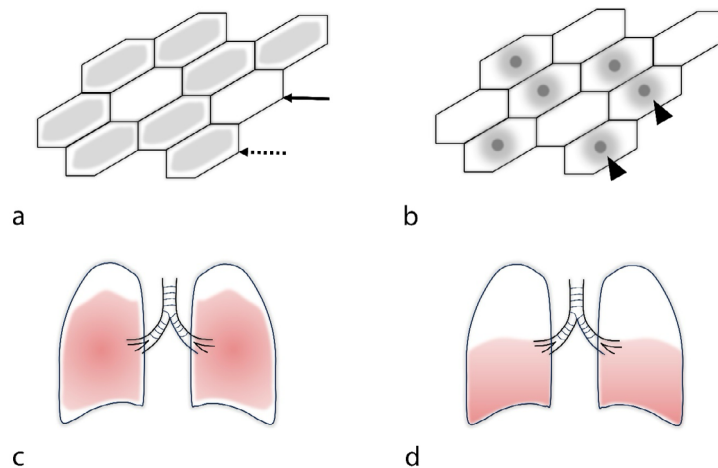


Figure 5. Schematic illustration of selected key findings of AIP (a, c) and DAH (b, d). a GGO (dotted arrow) with sparing of individual lobules (arrow) creating a geographic appearance in AIP. b Centrilobular consolidation with perilesional GGO (arrowheads) in DAH. c Distribution of AIP affecting the middle and lower lung parts with sparing of costophrenic angles. d Distribution of DAH with a more dominant affection of lower lung parts and sparing of the more apical segments. A sparing of the costophrenic angles was not observed. AIP = acute interstitial pneumonia, DAH = diffuse alveolar hemorrhage, GGO = ground glass opacities.

TABLE I. Overview of the HRCT findings in AIP and DAH of the presented VEXAS syndrome with reported incidence in the literature of each individual CT pattern for VEXAS syndrome, AIP, and DAH

HRCT pattern	Acute interstitial pneumonia	Diffuse alveolar haemorrhage	Reported incidence in VEXAS syndrome	Reported incidence in AIP	Reported incidence in DAH
Ground glass opacities	Bilateral, symmetric	Bilateral, perilesional, asymmetric	47-87% ^{7,3}	96-100% ^{10,17}	92-100% ^{17,21,22}
Consolidation	Few patchy areas	Asymmetric, centrilobular	49% ⁷	43-97% ^{10,17}	31-80% ^{17,21,22}
Septal thickening	Inter- and intralobular	interlobular	51% ⁷	53-84% ^{10,17}	30-38% ^{21,23}
Macronodules (> 3 mm)	Not present	Centrilobular	47% ⁷	<1% ¹⁷	50-64% ^{21,22}
Micronodules (< 3 mm)	Not present	Not present	38% ⁷	5% ¹⁷	20% ²⁵
Pleural effusion	Not present	Small right sided	9-53% ^{7,3,4}	22-31% ^{18,19}	14-23% ^{17,22}
Pericardial effusion	Not present	Not present	15% ⁷	Not present ^{10,17,18,19}	50% ²¹
Bronchiectasis	Not present	Not present	8-29% ^{7,4}	70-95% ¹⁰	13% ²¹
Tracheal chondritis	Not present	Not present	45% ¹⁶	Not present ^{10,17,18,19}	Not present ^{17,21,22,23}
Lymphadenopathy	Mediastinal and right hilar	Mediastinal and right hilar	29-58% ^{7,3}	8% ¹⁸	May be present ⁷
Pulmonary embolism	Not present	Not present	36% ¹⁶	Not present ^{10,17,18,19}	May be present ¹⁹
Distribution	Mid and lower lobes	Lower lobes	Not reported ^{7,3,4,16}	Lower lobes ¹⁷	Lower lobes ²¹
Costophrenic angles	Spared	Involved	Not reported ^{7,3,4,16}	Spared ²⁰	variable ^{12,17,21,22,23}

HRCT = High resolution computed tomography; AIP = acute interstitial pneumonia, DAH = diffuse alveolar hemorrhage, VEXAS = Vacuoles, E1 enzyme, X-linked, autoinflammatory, somatic.

organizing pneumonia, or bilateral unspecific lung infiltrates³. In the present case, severe pulmonary involvement occurred 3 years after the initial onset of the syndrome with a rapidly progressive respiratory failure and distinctive bilateral GGO. The diagnosis of an AIP at the first reported emergency visit was reasonable. AIP has a similar presentation as an acute respiratory syndrome (ARDS) and histologically correlates with diffuse alveolar damage presenting as rapid onset dyspnea⁸. The early exudative phase of AIP shows bilateral GGO with consolidations on the Gravity-dependent areas and an overall geographic appearance⁹, which was also seen in our patient. In the more advanced organizing phase, AIP shows signs of lung fibrosis with distortions of the normal lung architecture, traction bronchiectasis, and more dominant consolidation than GGO^{10,11}. Infectious pneumonia is an important differential diagnosis of AIP¹¹, but was rather unlikely in our case since no pathogen was isolated and serologic testing for infectious causes was negative.

DAH is a potentially life-threatening condition presenting with hemoptysis, anemia, lung infiltrates, and respiratory failure. DAH is most commonly caused by an underlying capillaritis in association with systemic vasculitis such as anti-neutrophil cytoplasmic antibody (ANCA)-associated vasculitis, Goodpasture's Syndrome, systemic lupus erythematosus and other connective tissue diseases. In such patients, chest CT

often reveals bilateral centrilobular consolidations with perilesional GGO, septal interlobular thickening, lower lung predominance, and sparing of the apical segments. Crazy-paving or hilar lymphadenopathy may eventually develop in later stages¹². A similar pattern was seen in our patient during the second admission. An underlying capillaritis as a cause for the DAH is possible in our case since VEXAS syndrome is frequently associated with vasculitis, most commonly LCV (31%) with case reports involving ANCA-associated types¹³. Some autoinflammatory diseases are associated with bleeding diathesis¹⁴, although we could not identify any reports in the literature regarding an association with VEXAS syndrome. Drug-induced DAH is in our case not plausible since the patient was not on any anticoagulation therapy and platelet counts were within normal ranges, making a role of ruxolitinib for increased bleeding risk unlikely¹⁵. Lymphadenopathy is an unspecific finding on both presented chest scans and has been reported in up to 58% of patients with VEXAS syndrome³.

Glucocorticoids and JAK inhibitors are commonly used in patients with VEXAS syndrome^{1,4} and the observed clinical response in our case is primarily attributed to this therapy. Antibiotics were initiated empirically until an infectious cause could be excluded. Ground glass pulmonary infiltrates were present on both chest CT scans, which are strongly associated with VEXAS syndrome⁴. Table I summarizes our ob-

servations of AIP and DAH in VEXAS syndrome, along with the reported incidence of individual findings in the literature. These entities are not exclusively specific to VEXAS syndrome; however, the table serves as a concise reference for the key findings associated with VEXAS syndrome, AIP, and DAH. Our observation of AIP and DAH is similar to those observed in patients without known VEXAS syndrome. A comparison of a larger sample is needed, given the general lack of publications regarding detailed assessments of acute pulmonary manifestations of this syndrome. An illustrative representation of CT key findings and lung involvement distribution is depicted in Figure 5. The role of CT in the surveillance of patients with VEXAS syndrome is not established since the risk of developing consecutive pulmonary fibrosis is still unknown³.

This report highlights two rare pulmonary manifestations of VEXAS syndrome and contributes to the limited literature on specific pulmonary manifestations. Identifying similar cases could enhance syndrome comprehension, potentially prompting routine chest CT screening implementation.

REFERENCES

1. Beck DB, Ferrada MA, Sikora KA, et al. Somatic Mutations in UBA1 and Severe Adult-Onset Autoinflammatory Disease. *N Engl J Med*. 2020; 383(27): 2628-2638. <https://doi.org/10.1056/NEJMoa2026834>
2. Vitale A, Caggiano V, Bimonte A, et al. VEXAS syndrome: a new paradigm for adult-onset monogenic autoinflammatory diseases. *Intern Emerg Med*. 2023; 18(3): 711-722. <https://doi.org/10.1007/s11739-023-03193-z>
3. Borie R, Debray MP, Guerdon AF, et al. Pleuropulmonary Manifestations of Vacuoles, E1 Enzyme, X-Linked, Autoinflammatory, Somatic (VEXAS) Syndrome. *Chest*. 2023; 163(3): 575-585. <https://doi.org/10.1016/j.chest.2022.10.011>
4. Bruno A, Gurnari C, Alexander T, Snowden JA, Greco R. Autoimmune manifestations in VEXAS: Opportunities for integration and pitfalls to interpretation. *Allergy Clin Immunol*. 2023; 151(5): 1204-1214. <https://doi.org/10.1016/j.jaci.2023.02.017>
5. Georjin-Lavialle S, Terrier B, Guedon AF, et al. Further Characterization of Clinical and Laboratory Features in VEXAS Syndrome: Large-scale Analysis of a Multicentre Case Series of 116 French Patients. *Br J Dermatol*. 2022; 186(3): 564-574. <https://doi.org/10.1111/bjd.20805>
6. Obiorah IE, Patel BA, Groarke EM, et al. Benign and malignant hematologic manifestations in patients with VEXAS syndrome due to somatic mutations in UBA1. *Blood Adv*. 2021; 5(16): 3203-3215. <https://doi.org/10.1182/bloodadvances.2021004976>
7. Casal Moura M, Baqir M, Tandon YK, et al. Pulmonary manifestations in VEXAS syndrome. *Respir Med*. 2023; 213: 107245. <https://doi.org/10.1016/j.rmed.2023.107245>
8. Oliveira DS, Araújo Filho JA, Paiva AFL, Ikari ES, Chate RC, Nomura CH. Idiopathic interstitial pneumonias: review of the latest American Thoracic Society/European Respiratory Society classification. *Radiol Bras*. 2018; 51(5): 321-327. <https://doi.org/10.1590/0100-3984.2016.0134>
9. Taniguchi H, Kondoh Y. Acute and subacute idiopathic interstitial pneumonias. *Respirology*. 2016; 21(5): 810-820. <https://doi.org/10.1111/resp.12786>
10. Ichikado K, Suga M, Müller NL, et al. Acute interstitial pneumonia: comparison of high-resolution computed tomography findings between survivors and nonsurvivors. *Am J Respir Crit Care Med*. 2002; 165(11): 1551-1556. <https://doi.org/10.1164/rccm.2106157>
11. Bouros D, Nicholson AC. Acute interstitial pneumonia. *Eur Respir J*. 2000; 15(2): 412-418. <https://doi.org/10.1034/j.1399-3003.2000.15b31.x>
12. Reisman S, Chung M, Bernheim A. A Review of Clinical and Imaging Features of Diffuse Pulmonary Hemorrhage. *AJR Am J Roentgenol*. 2021; 2016(6): 1500-1509. <https://doi.org/10.2214/AJR.20.23399>
13. Watanabe R, Kiji M, Hashimoto M. Vasculitis associated with VEXAS syndrome: A literature review. *Front Med (Lausanne)*. 2022; 15(9): 983939. <https://doi.org/10.3389/fmed.2022.983939>
14. Gutierrez MJ, Lapidus SK. Systemic Autoinflammatory Diseases: A Growing Family of Disorders of Overlapping Immune Dysfunction. *Rheum Dis Clin North Am*. 2022; 48(1): 371-395. <https://doi.org/10.1016/j.rdc.2021.07.011>
15. Arana Yi C, Tam CS, Verstovsek S. Efficacy and safety of ruxolitinib in the treatment of patients with myelofibrosis. *Future Oncol*. 2015; 11(5): 719-733. <https://doi.org/10.2217/fon.14.272>
16. Kouranloo K, Ashley A, Zhao SS, Dey M. Pulmonary manifestations in VEXAS (vacuoles, E1 enzyme, X-linked, autoinflammatory, somatic) syndrome: a systematic review. *Rheumatol Int*. 2023; 43(6): 1023-1032. <https://doi.org/10.1007/s00296-022-05266-2>
17. Tomiyama N, Müller NL, Johkoh T, et al. Acute respiratory distress syndrome and acute interstitial pneumonia: comparison of thin-section CT findings. *J Comput Assist Tomogr*. 2001; 25(1): 28-33. <https://doi.org/10.1097/00004728-200101000-00005>
18. Johkoh T, Müller NL, Taniguchi H, et al. Acute interstitial pneumonia: thin-section CT findings in 36 patients. *Radiology*. 1999; 211(3): 859-863. <https://doi.org/10.1148/radiology.211.3.r99jn04859>
19. Primack SL, Hartman TE, Ikezoe J, Akira M, Sakatani M, Müller NL. Acute interstitial pneumonia: radiographic and CT findings in nine patients. *Radiology*. 1993; 188(3): 817-820. <https://doi.org/10.1148/radiology.188.3.8351354>
20. Palmucci S, Roccasalva F, Puglisi S, et al. Clinical and radiological features of idiopathic interstitial pneumonias (IIPs): a pictorial review. *Insights Imaging*. 2014; 5(3): 347-364. <https://doi.org/10.1007/s13244-014-0335-3>
21. Spira D, Wirths S, Skowronski F, et al. Diffuse alveolar hemorrhage in patients with hematological malignancies: HRCT patterns of pulmonary involvement and disease course. *Clin Imaging*. 2013; 37(4): 680-6. <https://doi.org/10.1016/j.clinimag.2012.11.005>
22. Kloth C, Thaiss WM, Beck R, et al. Potential role of CT-textural features for differentiation between viral interstitial pneumonias, pneumocystis jirovecii pneumonia and diffuse alveolar hemorrhage in early stages of disease: a proof of principle. *BMC Med Imaging*. 2019; 19(1): 39. <https://doi.org/10.1186/s12880-019-0338-0>
23. Witte RJ, Gurney JW, Robbins RA, et al. Diffuse pulmonary alveolar hemorrhage after bone marrow transplantation: radiographic findings in 39 patients. *AJR Am J Roentgenol*. 199; 157(3): 461-4. <https://doi.org/10.2214/ajr.157.3.1872226>